

Introduction: Cerebrovascular reactivity (CVR) is a measure of cerebral perfusion reserve and has been shown to be significantly reduced in patients with sickle cell disease (SCD), indicating haemodynamic impairment [1, 2]. This can lead to insufficient oxygen supply during periods of increased cerebral metabolism resulting in subclinical ischemic white matter (WM) injury which can be detected using diffusion imaging. Previous studies have demonstrated changes in WM integrity and architecture in SCD [3, 4, 5]. However the underlying vascular contributions to WM damage in SCD are not understood. Animal models suggest that impaired hemodynamics precede white matter lesions in ischemic small vessel disease [6] and therefore we hypothesize that there will be an association between cerebrovascular reactivity and measures of fractional anisotropy (FA) as measured with diffusion tensor imaging (DTI), reflecting the underlying vascular contribution to changes in WM integrity in SCD.

Methods: Four SCD patients (3 females and 1 male, 9-17 years) and five healthy age-matched controls (4 males, 1 female, 14-18 yrs) were imaged on a clinical 3T MRI scanner using a 32-channel head coil. Blood oxygen level dependent (BOLD) CVR data were acquired during a hypercapnic challenge. The hypercapnic challenge was administered using the RespirAct system and consisted of 60s normocapnia ($P_{ET}CO_2 = 40\text{mmHg}$), followed by 45s of hypercapnia ($P_{ET}CO_2 = 45\text{mmHg}$, this was repeated for 5 cycles). BOLD data were acquired with TR/TE = 2000/30ms, FOV = 220mm, slices = 25, slice thickness = 4.5mm, volumes = 240. T₁-weighted anatomical images were acquired with TR/TE = 2300/2.96 ms, FOV = 256mm, voxel size = 1x1x1mm, flip angle = 9°. DTI data were acquired using a single-shot EPI sequence (TR/TE = 9000/90 ms, FOV = 244x244x175 mm, voxel size = 2 x 2 x 2.5 mm³, 70 slices, slice thickness = 3mm) with 30 non-collinear diffusion gradient directions ($b = 1000$ and 0 s/mm^2). FLAIR images were acquired for detection of WM lesions (TR/TE = 9000/85 ms, FOV = 220mm, slices = 25, slice thickness = 4.5 mm).

Analysis: CVR maps were computed using FSLv4.1 by correlating the voxel-wise BOLD signal changes to the end-tidal CO₂ waveform. Each voxel value was then normalized to the temporal mean BOLD signal to convert into CVR, followed by co-registration to the anatomical space. DTI data were processed using FSL v4.1 with eigenvalues and eigenvectors calculated using dtifit to create maps of FA. T₁ anatomicals were segmented and divided into 8 WM ROIs using a template mask [4]. Statistical comparisons were made using SPSSv22.

Results: SCD patients showed a significant global reduction in WM CVR (independent samples t-test, $p=0.04$) and FA ($p=0.01$) in comparison to healthy controls, however, no statistical differences were observed regionally. Global correlation analysis identified a significant positive correlation between CVR and FA (pearson product moment correlation coefficient, $r^2 = 0.975$, $p = 0.03$). Regional analysis showed significant positive correlation between CVR and FA in the right frontal cortex (pearson product moment correlation coefficient, $r^2 = 0.997$, $p = 0.02$), after post-hoc Bonferroni test. No statistical changes or correlations were observed (globally or regionally) in healthy controls between CVR and anisotropy measures. No WM lesions were evident on FLAIR images evident across subjects.

Discussion: This is the first study to provide evidence of a linear relationship between the degree of WM structural integrity, measured by FA, and CVR in SCD. This association is established before WM damage is evident on anatomical MR images. These results suggest that impaired CVR leads to low-grade ischemic damage and resulting WM structural degradation in SCD. However, further investigation into the causal relationship between hemodynamic impairment and white matter structural integrity is required via longitudinal studies, which may help shed light on the mechanisms underlying cognitive decline observed in SCD [5].

References: [1] Nur et al., Blood (2009), [2] Kim et al., ISMRM (2014) [3] Balci et al., AJR (2012) [4] Sun et al., AJNR, (2012) [5] Scantlebury et al. J. Ped. Hematol. Oncol. (2011), [6] Joutel et al. J. Clin. Invest. (2010).

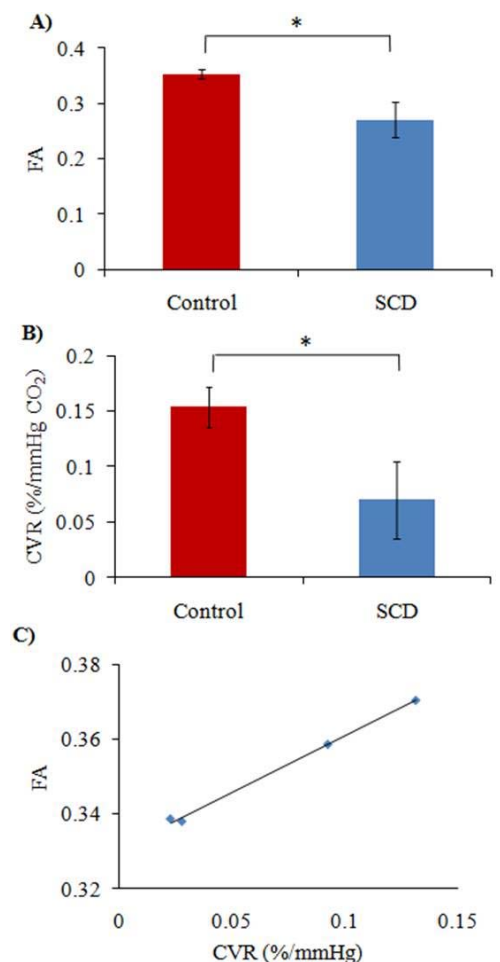


Figure 1: A significant reduction was observed in white matter (WM) measures of (A) fractional anisotropy (FA) and (B) cerebrovascular reactivity (CVR) in patients with sickle cell disease (SCD). Data averaged across subjects (\pm SEM). C) A significant positive correlation was observed between WM FA and WM cerebrovascular reactivity (CVR) in the right frontal cortex. * denotes $p < 0.05$