

Chemical exchange saturation transfer (CEST) MR imaging of rat liver with fasting or CCl₄ intoxication

Shuzhong Chen¹, Min Deng¹, Jing Yuan², and Yi-Xiang Wang¹

¹Department of Imaging and Interventional Radiology, The Chinese University of Hong Kong, Shatin, N.T., Hong Kong, ²Medical Physics and Research Department, Hong Kong Sanatorium & Hospital, Happy Valley, Hong Kong

Purpose: Chemical exchange saturation transfer (CEST) MRI is a promising molecular imaging technique which enables indirect detection of metabolites with exchangeable protons or molecules. Amide proton transfer (APT) MRI has been used to image amide protons from endogenous mobile proteins and peptides in tissue and has been applied for various clinical applications [1]. GlycoCEST was demonstrated to be able to detect glycogen in the excised perfused mouse liver and showed potential to study various liver diseases [2]. However, these two technologies have not been successfully applied *in vivo* liver at 3T. To this end, we aim to investigate APT and glycoCEST MRI at 3T in rat liver with fasting and CCl₄ injection in this study.

Materials and Methods: The local animal ethics committee approved this study. Twelve male Sprague-Dawley rats with a weight of 200-250g were scanned using a Philips Achieva 3T scanner (Philips Healthcare, Best, the Netherlands) with a body coil for transmission and a wrist coil for reception. After conventional MRI using T2-weighted images to localize the anatomy, APT and glycoCEST images were acquired using a single-slice turbo-spin-echo (TSE) sequence. A continuous rectangular RF pulse was performed for saturation, with a B₁ field strength of 3 μ T and a fixed duration of 300 ms. The major imaging parameters were: TSE factor = 11; TR = 2350 ms, TE = 6 ms, field of view (FOV), 80 \times 65 mm²; voxel size, 1.25 \times 1.25 mm²; slice thickness, 2 mm; number of signal averages (NSA), 5. Baseline image was obtained first without using saturation pulse, and then the saturated images were acquired at the offsets of (0, \pm 0.25, \pm 0.5, \pm 0.75, \pm 1, \pm 1.25, \pm 1.5, \pm 1.75, \pm 2, \pm 2.25, \pm 2.5, \pm 2.75, \pm 3, \pm 3.25, \pm 3.5, \pm 3.75, \pm 4, \pm 4.25, \pm 4.5, \pm 4.75, \pm 5) parts per million (ppm).

Image Analysis: Data analysis was performed by home-developed Matlab (MathWorks, Natick, MA, USA) programs. For each voxel, Z-spectrum was first least-square fitted by a 12th-order polynomial model and interpolated to a finer resolution of 0.001 ppm. The actual water resonance was assumed to be at the lowest intensity frequency of the fitted Z-spectrum. Then the B₀ field inhomogeneity ΔB_0 map was obtained and the lowest intensity frequency of the interpolated Z-spectrum was shifted to 0 ppm of the offset axis to correct ΔB_0 . The magnitude of the CEST effect was quantified as an MT asymmetry ratio (MTR_{asym}): $MTR_{asym}(\Delta\Omega) = [S(-\Delta\Omega) - S(\Delta\Omega)] / S_0$, where $\Delta\Omega$ donates the shift difference between irradiation frequency and the water frequency. S and S₀ are the saturated and nonsaturated intensities. The integrated MTR_{asym} signal was qualified for APT value at 3.5 ppm and glycoCEST MTR value in the frequency range $\Delta\Omega = 0.5$ to 1.5 ppm. The voxel-wise coefficient of determination R² was also calculated to evaluate the Z-spectrum fitting. The voxel which showed relatively poor goodness-of-fit (R² < 0.99) would be excluded for analysis.

Results: In the CCl₄ injection detection (Fig 1A), the rat liver baseline APT value was $2.33 \pm 0.65\%$ and the glycoCEST value was $0.24 \pm 0.20\%$. 48 hours post the initiation of CCl₄ insult, the liver APT value was $1.19 \pm 0.80\%$, decreased by 48.93% (Fig 2) and the glycoCEST value was $-0.12 \pm 0.62\%$, decreased by 150%. By comparing the pre-fasting and post-fasting (Fig 1B), APT value after fasting ($0.94 \pm 0.71\%$) was lower than before fasting ($2.36 \pm 0.74\%$, decreased by 60.17%). The mean glycoCEST in range 0.5 to 1.5 ppm was also lower after overnight fasting. The mean MTR_{asym} of glycoCEST was $0.47 \pm 0.25\%$ before fasting and $-0.43 \pm 0.42\%$ after fasting, decreased by 191%.

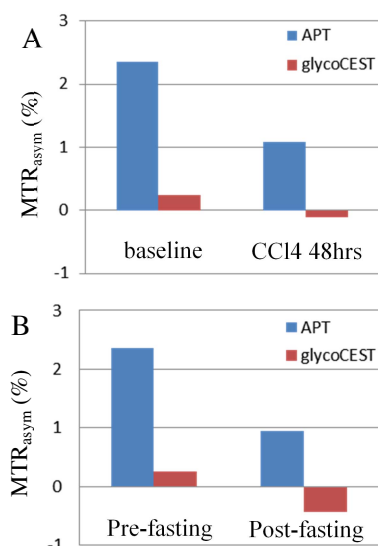


Fig 1. The change in MTR_{asym} of APT and glycoCEST (A) before and after 48 hours CCl₄ injection, (B) before and after 24 hours fasting.

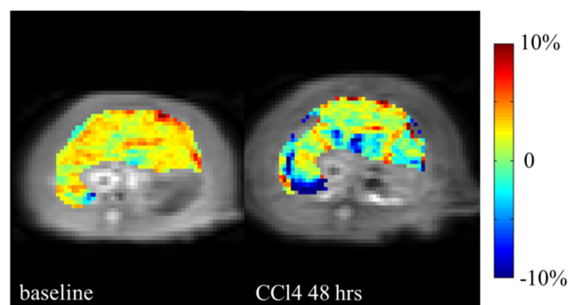


Fig 2. Typical APT map (MTR_{asym} at 3.5 ppm) before CCl₄ injection and after CCl₄ injection.

Discussion: The results indicate that both APT and glycoCEST value decrease after CCl₄ 48 hours injection and 24 hours fasting. However, compared with APT, glycoCEST shows high intra- and inter-subject standard deviation in both experiments. This may due to the rapid exchange rate of glycogen hydroxyl protons and their proximity to the water resonance [3]. The reliability of glycoCEST in *in vivo* liver at 3T should be further investigated. The observed change in APT reflected the alteration of amide proton levels by injecting CCl₄ and fasting.

References:

- [1] Wen Z, et al. Neuroimage 51(2):616-22 (2010); [2] van Zijl PC, et al. PNAS 104:4359-4364 (2007); [3] Dula, et al. Radiology (2014) DOI: <http://dx.doi.org/10.1148/radiol.14140762>.