

Longitudinal CEST Imaging of Spinal Cord Injury in Monkeys: Fingerprints of Cyst

Feng Wang^{1,2}, Zhongliang Zu^{1,2}, Tung-Lin Wu², John C. Gore^{1,2}, and Li Min Chen^{1,2}

¹Radiology and Radiological Sciences, Vanderbilt University, Nashville, TN, United States, ²Institute of Imaging Sciences, Vanderbilt University, Nashville, TN, United States

Target audience: Investigators who are interested in spine imaging or CEST.

Background: Non-human primates provide a valuable pre-clinical model for studying spinal cord injuries (SCI). The metabolites and byproducts from SCI exhibit CEST (Chemical Exchange Saturation Transfer) effects due to their exchangeable protons on hydroxyl, amine and amide residues. Our goal was to record and interpret the CEST signals found in the z-spectra of abnormalities formed after SCI, and to compare different CEST mapping schemes of SCI for evaluating regional changes around the sites of lesions during the spontaneous recovery period after injury.

Methods: High-resolution MR images were acquired using a saddle-shaped coil from anesthetized (isoflurane 0.5-1.5%) squirrel monkeys at 9.4T. Three monkeys underwent surgery to introduce unilateral dorsal column lesions at C4-C5 level, and they were scanned at different time points for up to 24 weeks after the surgery. CEST imaging was performed using a continuous wave (CW) (5.0s, 1.0 μ T) irradiation pulse followed by a 2-shot SE-EPI readout with TR of 7.5 s, TE of 17.6 ms, resolution at 0.5x0.5x1 mm³, RF offsets from -2000 Hz to 2000 Hz with an interval of 80 Hz. A control scan was performed with an RF offset of 100 kHz. A peak-fitting algorithm was used to decompose overlapping peaks from amides (I), amines (II), hydroxyls (III), direct saturation on free water (IV), and aliphatic compounds (V) around 3.5, 2.2, 1.2, 0 and -3.3 ppm RF offsets, respectively (Fig. 1B). The averaged regional z-spectrum was fit as the sum of 5 peaks of Lorentzian bands. CEST features were evaluated regionally and longitudinally. Parametric maps were extracted from z-spectra. Conventional MTR_{asym} from asymmetric analysis at characteristic RF offsets, 3-point amide proton transfer (APT*), 3-point APTi* and T₁-corrected APT_{T1c}* based on inverse z-spectrum analysis [1], 2-point solid MT*, 3-point NOE*, and correlation maps were obtained for comparison. CEST images were acquired along with magnetization transfer (MT) and DTI during the recovery of SCI.

Results: Images with MT contrast (MTC) clearly detected the formation of cysts after SCI (Fig. 1). DTI results suggested that each cyst had very low cellular density. Amide, amine and hydroxyl CEST signals from metabolites, nuclear Overhauser enhancements (NOE) from mobile aliphatic

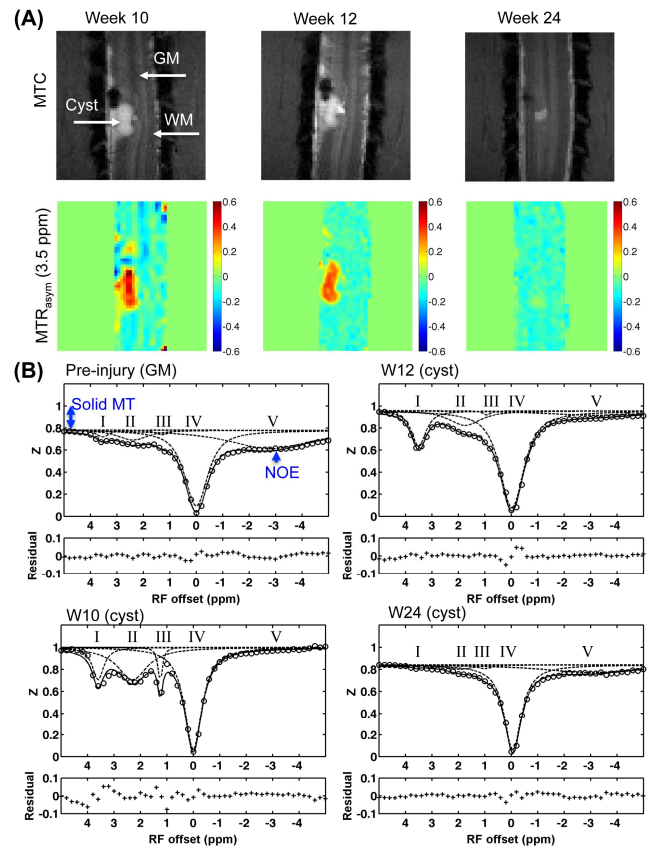


Figure 1. Longitudinal comparison after SCI. (A) MTC images and MTR_{asym} maps. (B) Peak fitting showing the variation of features in cyst.

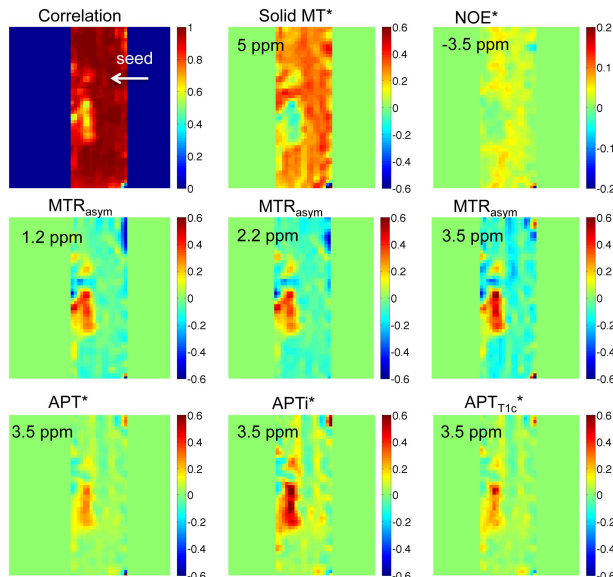


Figure 2. Parametric maps 10 weeks after spinal cord injury.

and T-1-corrected steady-state pulsed CEST-MRI - application to pH-weighted MRI of acute stroke. NMR Biomed 2014, 27(3):240-252.

macromolecules, and solid magnetization transfer (MT) effects from immobile macromolecules such as proteins were extracted from z-spectra and compared regionally in SC (Fig. 1B). Compared to regular gray matter (GM), the amide, amine and hydroxyl levels were high while the solid MT and NOE were low in cyst at the peak point of cyst progression (Fig. 1B). Longitudinally, all the subjects exhibited recovery from SCI with the shrinking of the cyst and reduction of CEST effects at/around the lesion site (Fig. 1A). To enhance the contrast for abnormalities from SCI, different mapping approaches based on z-spectra were compared in Figure 2. Cyst showed much smaller correlation coefficients than regular tissue when z-spectra were compared to regular GM pixel-by-pixel. Low solid MT* and NOE*, and high CEST effects were observed in cyst at the peak point during recovery. NOE showed a large effect on MTR_{asym} of regular tissue, especially white matter (Fig. 2). The APTi* from the inverse z-spectrum analysis enhanced the APT contrast for the abnormal features around the lesion site, while T₁-corrected APT_{T1c}* brought the amide contrast of cyst back due to its long T₁ relaxation time. At the peak point during the recovery of SCI, abnormal tissues around the lesion site also showed significant increased CEST effects but on a smaller scale than cyst (Fig. 2).

Conclusions: Characteristic features extracted from z-spectra could enable the non-invasive assessment of spontaneous recovery from SCI, regionally and longitudinally.

Reference: [1] Zaiss M, Xu JZ, Goerke S, Khan IS, Singer RJ, Gore JC, Gochberg DF, Bachert P: **Inverse Z-spectrum analysis for spillover-, MT-,**