

# Reduced visual cortex perfusion without volume loss in mild to moderate hypertension

Diandian Huang<sup>1</sup>, Xin Lou<sup>1</sup>, Lin Ma<sup>1</sup>, and Zhengyu Zhou<sup>2</sup>

<sup>1</sup>radiology, Chinese PLA General Hospital, Beijing, Beijing, China, <sup>2</sup>MR Research Center, GE Health care, Beijing, China

## PURPOSE

Visual cortex pathology in hypertension is associated with progressive long-term ocular disability. Detection of visual cortex abnormalities in mild to moderate hypertension may therefore be valuable in understanding and predicting the ocular long-term course. However, structural MRI measures such as volume measurement have only shown abnormalities without the region of visual cortex in hypertension. We therefore investigated for evidence of abnormality in visual cortex perfusion, consistent with metabolic dysfunction and the volume measurement, in mild to moderate hypertension.

## METHODS

27 mild to moderate hypertensive patients without retinopathy and 32 age-matched healthy controls underwent 3 Tesla MRI with a three dimensional pseudo-continuous arterial spin labelling(3D PCASL) sequence to quantify visual cortex perfusion and a volumetric T1-weighted sequence to measure the volume. Region of interest analysis was used to compare regional visual cortex (including brodmann 17, 18 and 19, Fig1) perfusion and volume measures in patients and controls. Independent t test was performed to compare the inter-group difference in the significance of modifications in cerebral blood flow (CBF) and the volume. Paired t tests were applied to the comparison of the CBF between the left and right brodmann areas in the groups respectively. The measurement of the ocular retinal pathology was using the fluorescein angiography.

## RESULTS

Compared with the control group, the hypertensive group exhibited reduced CBF values in the binocular cortex including the brodmann17, 18 and 19(P<0.05) (Table 1 and Fig.2). Nevertheless, no statistical significant difference in the CBF values was observed in the comparison between the left and the right brodmann 17 and 18 areas while the evident significance in the brodmann 19 remained similarly in the separated two groups. There was not evident volume loss in the analysis of visual cortex in patients versus controls (Table 2).

## CONCLUSION

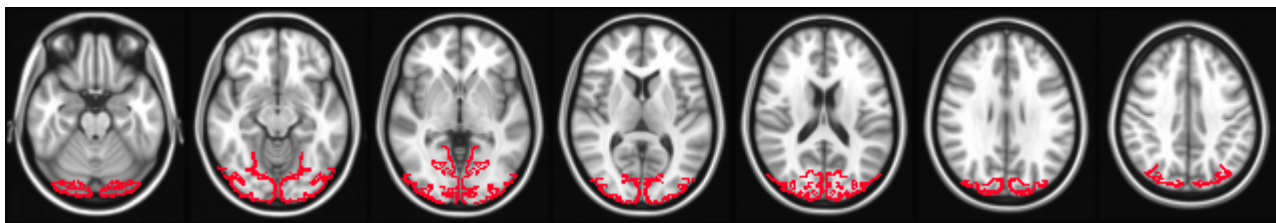
The decrease in visual cortex perfusion in the absence of volume loss is consistent with cerebrovascular metabolic dysfunction in mild to moderate hypertension in the absence of the retinopathy. We suspect there is a variety of the hemodynamics prior to the change of the morphology in the visual cortex in hypertension. However, future studies in larger cohorts and longitudinal follow-up are needed to investigate the functional and prognostic significance of the early visual cortex perfusion deficits observed.

**Table.1 The mean and SD CBF value for the ROIs between the control group and the hypertensive group**

ROI Name	Control group		Hypertensive group		P value	Different value (ml/100g /min)
	Mean (ml/100 g/min)	SD (ml/100 g/min)	Mean (ml/100 g/min)	SD (ml/100 g/min)		
Left brodmann 17	48.6	10.20	41.42	11.00	0.012	7.18
Right brodmann 17	48.53	11.41	38.68	14.75	0.005	9.85
Left brodmann 18	46.99	9.54	38.39	9.51	0.001	8.60
Right brodmann 18	47.02	9.08	37.64	10.86	0.001	9.38
Left brodmann 19	48.34	10.22	39.83	8.32	0.001	8.51
Right brodmann 19	46.99	9.51	38.03	8.41	0.000	8.96

\*Perfusion was measured in units of mL/100 cc gray matter/min.

**Fig.1 ROIs representation of the study**



**Table.2 The volume comparison of the visual cortex between the control group and the hypertensive group**

ROI Name	Control group		Hypertensive group		P value
	Mean	SD	Mean	SD	
Brodmann 17	13596.94	358.6687	13796.61	181.183	0.58
Brodmann 18	14584.67	372.0553	14827.37	210.8954	0.517
Brodmann 19	14743.12	369.315	15046.96	213.6804	0.414

\*volume was measured in units of mm<sup>3</sup>

**Fig.2 The histogram with the mean CBF values between the groups**

