

Selective Musculoskeletal MRI Using ZTE Imaging with Long-T2 Suppression

Markus Weiger¹, Mingming Wu^{1,2}, Moritz Christoph Wurnig³, David Kenkel³, Andreas Boss³, Gustav Andreisek³, and Klaas Paul Pruessmann¹
¹Institute for Biomedical Engineering, University and ETH Zurich, Zurich, Switzerland, ²Institute of Biomedical Engineering, Karlsruhe Institute of Technology, Karlsruhe, Germany, ³Institute for Diagnostic and Interventional Radiology, University Hospital Zurich, Zurich, Switzerland

Introduction MRI offers excellent soft tissue contrast whereas more rigid tissues, characterized by rapid transverse relaxation, appear dark in conventionally acquired images. In particular, in musculoskeletal (MSK) applications, tissues such as bone, tendons, or ligaments give only negligible signal, hence inhibiting any direct observation of tissue condition. However, dedicated short-T2 techniques with ultra-short or zero TE enable direct imaging of such tissues¹⁻⁶. In particular, the 3D radial zero echo time (ZTE) technique⁷⁻⁹ is able to capture short-T2 signals with high bandwidth, efficiency, and robustness. Yet the feature of detecting signals from a wide T2 range is accompanied by a lack of contrast between the corresponding tissues. Therefore, various approaches have been proposed to reduce long-T2 signal based on suppression and/or difference schemes^{10,11}. In this work, specific properties of the ZTE technique are taken into account to develop efficient long-T2 suppression, thus enabling selective, direct MSK MRI akin to CT contrast.

Methods Considering the intrinsic 3D nature of the ZTE technique as well as its short TRs (~1ms), for efficient long-T2 suppression the segmented scheme in Fig. 1 is suggested. Timing parameters and flip angles were first optimized by means of simulations and then refined empirically during experiments. In a first simulation step, the flip angle of the suppression pulse was determined. It was found that in the quasi-steady-state of the magnetization as interrupted by the suppression period, better signal reduction is obtained for 180°-inversion than for 90°-saturation pulses. With inversion, smaller amplitudes are achieved and signal cancellation occurs due to oscillation around zero. Hence, inversion pulses were designed¹² with suitable T2 selectivity and a bandwidth adapted to the expected off-resonance range. The transverse magnetization M_T was calculated as a function of T2 and T1, using TR = 1 ms, $T_{sup} = 10$ ms, $T_{spoil} = 5$ ms, $T_{seg} = 50$ ms, $T_{rec} = 0$. Best results were achieved for a relatively large ZTE excitation flip angle of 10°. Figure 2 shows that M_T decreases not only for larger T2 but also with increasing T1. Muscle and fat are reduced to ~10% of the unsuppressed level whereas bone M_T is approximately halved, leading to increased contrast. Starting from these parameters, further experimental optimization revealed that in the chosen case, a recovery delay of $T_{rec} = 55$ ms is required to obtain the desired contrast. ZTE imaging was performed with the above parameters and 3D isotropic geometry, matrix = 128, FOV = 60 mm, pulse = 2 μ s, signal bandwidth = 200 kHz, readout = 320 μ s, k-space gap = 2 nominal dwells, 51896 radial spokes, NSA = 2 or 8, and scan time per average 52 s without and 125 s with suppression. Measurements were performed on a fresh sample of a lamb forefoot joint, using a 4.7 T Bruker small animal scanner.

Results Figure 3 shows ZTE results obtained with different contrast options compared with gradient echo and μ CT images. Opposed to echo data (a), considerable signal from trabecular and cortical bone water is observed with ZTE without suppression (b). Suppressing fat only leaves signal from bone water, cartilage, and muscle (c). Suppressing water only primarily reduces the latter two (d). Combined suppression results in a bone-selective image (e) which closely resembles the bone density obtained with μ CT (f). The sagittal view (g) furthermore shows a selective depiction of a tendon which cannot be identified in the μ CT image (h).

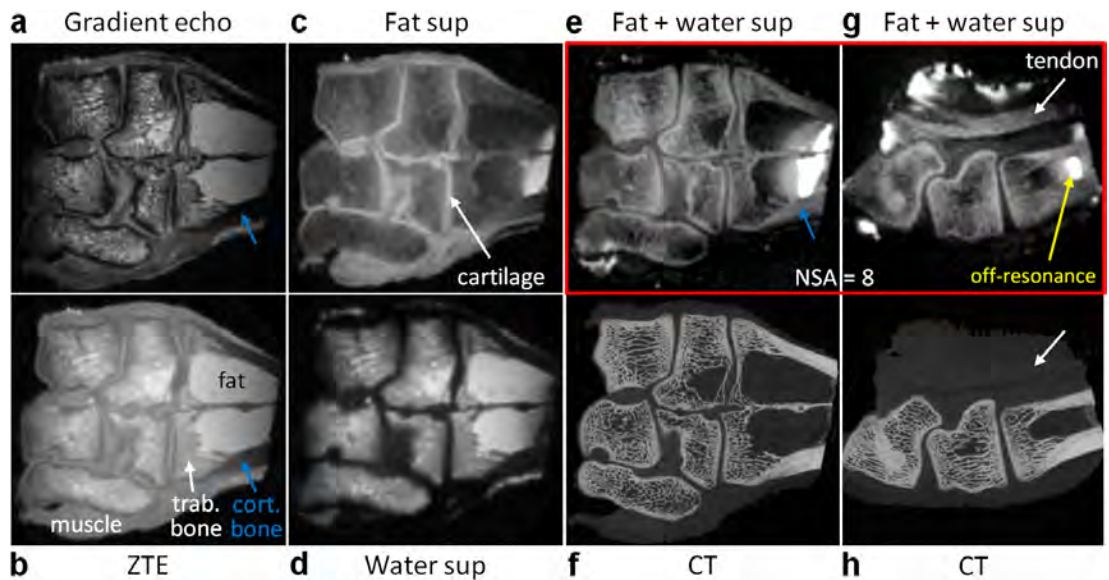


Figure 3 (a) Gradient echo and (b)-(e)+(g) ZTE imaging of a lamb joint with different suppression options; (f)+(h) μ CT data.

Discussion In this work, direct, selective MSK MRI was enabled by ZTE imaging with long-T2 suppression of both water and fat. Thus, images were acquired showing signal primarily from short-T2 tissues, namely bone and tendon. A segmented scheme with simulation- and experiment-based parameter optimization led to an acceptable scan time increase of 140%. A critical issue was imperfect suppression due to off-resonance at sample edges which, however, is expected to be more benign in vivo. The demonstrated capability of emulating CT contrast might contribute to efforts for MRI-based bone density measurements.

References 1. Du J, NMR Biomed 26 (2013) 489. 2. Wehrli FW, JMR 229 (2013) 35. 3. Wu YT, MRM 50 (2003) 59. 4. Grodzki DM, MRM 67 (2012) 510. 5. Weiger M, Bone 54 (2013) 44. 6. Luhach I, MRM 72 (2014) 858. 7. Hafner S, MRI 12 (1994) 1047. 8. Madio DP, MRM 34 (1995) 525. 9. Weiger M, eMagRes 1 (2012) 311. 10. Gold GE, MRM 34 (1995) 647. 11. Rahmer J, MAGMA 20 (2007) 83. 12. Larson PEZ, MRM 56 (2006) 94.

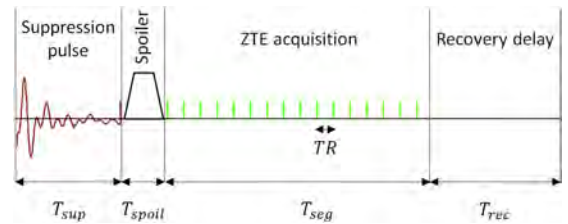


Figure 1 Sequence scheme for segmented ZTE imaging with long-T2 suppression of water and/or fat.

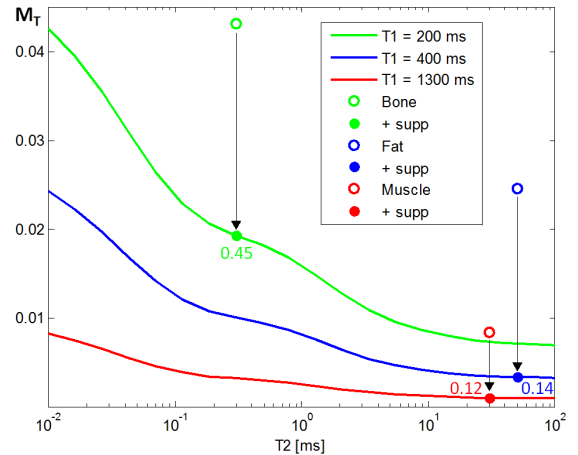


Figure 2 Simulated quasi-steady-state transverse magnetization of ZTE imaging with long-T2 suppression of both water and fat.