

DIFFUSION-WEIGHTED MAGNETIC RESONANCE IMAGING IN PARTIALLY NEPHRECTOMIZED KIDNEYS

Moritz Jörg Schneider¹, Olaf Dietrich¹, Katharina Stella Winter¹, Maximilian Reiser¹, Michael Staehler², and Mike Notohamiprodjo³

¹Institute for Clinical Radiology, Ludwig-Maximilians-University Hospital Munich, Munich, Bavaria, Germany, ²Department of Urology, Ludwig-Maximilians-University Hospital Munich, Munich, Bavaria, Germany, ³Department of Diagnostic and Interventional Radiology, University Hospital Tuebingen, Tuebingen, Baden-Württemberg, Germany

Target audience: MR physicists and radiologists.

Purpose: To investigate the effects of partial nephrectomy in kidneys with solid renal masses on the apparent diffusion coefficient (ADC) and on intravoxel incoherent motion (IVIM)[1] based parameters using diffusion-weighted magnetic resonance imaging (DW-MRI).

Methods: The study was approved by the local ethics committee and written informed consent was obtained from all patients. 15 patients with renal masses underwent 2 examinations, the first one prior to and the second one 1 week after partial nephrectomy. One patient only had 1 kidney, therefore a total of 14 non-nephrectomized (group 1) and 15 partially nephrectomized kidneys (group 2) were assessed with DW-MRI. The diffusion-weighted images were acquired on a clinical 3-T scanner (Magnetom Verio; Siemens Healthcare) with a dedicated 6 element body array matrix coil and 6 elements of the integrated spine coil. To obtain trace-weighted images, diffusion tensor imaging (DTI) was performed in the coronal plane using a single-shot spin-echo sequence with echoplanar imaging readout (TR = 5400 ms; TE = 73 ms; 6 diffusion directions; 2 averages; voxel size = 2.2 × 2.2 × 6 mm³; 25 slices; slice gap = 1.2 mm; parallel imaging factor 2 (GRAPPA); fat suppression; acquisition time = 648 s). A total of 10 diffusion-weightings (b-values) were acquired (b = 0; 10; 30; 50; 80; 120; 250; 400; 600; 800 s/mm²). Prior to calculating the trace, the diffusion tensor images were rigidly registered along the b-value dimension using a Fourier cross-correlation method to keep bulk-motion from affecting the parameters. The trace-weighted images were registered once more before using a monoexponential model ($S(b) = S_0 \times \exp(-b \times ADC)$) fit to calculate ADCs and a segmented biexponential fitting approach[2] to calculate voxelwise IVIM parameters ($S(b) = S_0 \times (f \times \exp(-b \times (D_{slow} + D_{fast})) + (1 - f) \times \exp(-b \times D_{slow}))$); with tissue diffusion D_{slow} , perfusion induced pseudodiffusion D_{fast} and the perfusion fraction f , representing the proportion of the initial signal intensity $S(0)$ attributed to blood). The median value inside multi-slice (min. 3 slices) regions of interest encompassing the kidney cortex was then used as representative value for each parameter, respectively. To compare parameters between baseline and follow-up measurement the paired Wilcoxon signed-rank test was used, to compare non-nephrectomized and partially nephrectomized kidneys the non-paired Mann-Whitney U test was used. P-values of less than 0.05 were considered statistically significant.

Results: Mean values and standard deviation of ADCs and IVIM parameters for each kidney group and measurement are listed in Table 1. None of the parameters derived from the baseline examination prior to partial nephrectomy revealed statistically significant differences between the two groups, whereas the follow-up measurement showed significant differences for the parameters ADC ($p < 0.001$), D_{fast} ($p = 0.02$) and most pronounced for f ($p < 0.001$). Comparing baseline and follow-up (Figure 1), partially nephrectomized kidneys showed a significant decrease for ADC ($p < 0.01$), D_{fast} ($p = 0.02$) and again most pronounced for f ($p < 0.01$). Non-nephrectomized kidneys expressed a significant increase for ADC ($p < 0.01$) as well as f ($p = 0.03$).

Table 1: Mean values and standard deviation of ADC and IVIM parameters for each kidney group and measurement.

Kidney group	ADC	ADC	D_{slow}	D_{slow}	D_{fast}	D_{fast}	f	f
	(10 ⁻³ mm ² /s)	(10 ⁻³ mm ² /s)	(10 ⁻³ mm ² /s)	(10 ⁻³ mm ² /s)	(10 ⁻³ mm ² /s)	(10 ⁻³ mm ² /s)	%	%
	Baseline	Follow-up	Baseline	Follow-up	Baseline	Follow-up	Baseline	Follow-up
Non-nephrectomized	2.47±0.24 [†]	2.66±0.30 [†]	2.02±0.18	2.11±0.21	8.70±1.62	9.52±2.65	19.3±2.7 [†]	21.5±4.0 [†]
Nephrectomized	2.50±0.28 [†]	2.29±0.18 [†]	2.05±0.23	1.99±0.12	8.58±1.79 [†]	7.25±1.66 [†]	19.2±3.0 [†]	13.7±4.4 [†]

Note: Statistically significant difference between nephrectomized and non-nephrectomized kidneys.

[†]Statistically significant difference between first and second measurement.

Discussion: The baseline measurements depict comparable values in the two groups for all parameters, suggesting equal kidney functionality prior to partial nephrectomy. ADC values in partially nephrectomized kidneys were significantly lower in the follow-up measurement; however, as implied by the results of the biexponential analysis, this decrease is likely to be caused by reduced perfusion. Accordingly, the tissue diffusion coefficient D_{slow} did not show any significant changes, while the perfusion fraction f as well as D_{fast} was significantly lower in the follow-up measurement, indicating reduced blood volume and blood flow velocity. In contrast, non-nephrectomized kidneys revealed an increase of ADC values as well as of the perfusion fraction f , which may be due to compensation of the reduced functionality of the partially nephrectomized kidney.

Conclusion: In this study we have shown that DW-MRI derived parameters are sensitive to partial nephrectomy in kidneys and are promising tools to assess kidney functionality. Biexponential analysis of diffusion-weighted images to obtain IVIM parameters appears to deliver more insight into kidney physiology but needs to be further validated by comparison with established methods such as dynamic contrast enhanced MRI.

References: [1] Le Bihan D et al. Radiology 1988;168:497-505, [2] Wirestam R et al. Acta Radiol. 2001;42(2):123-8

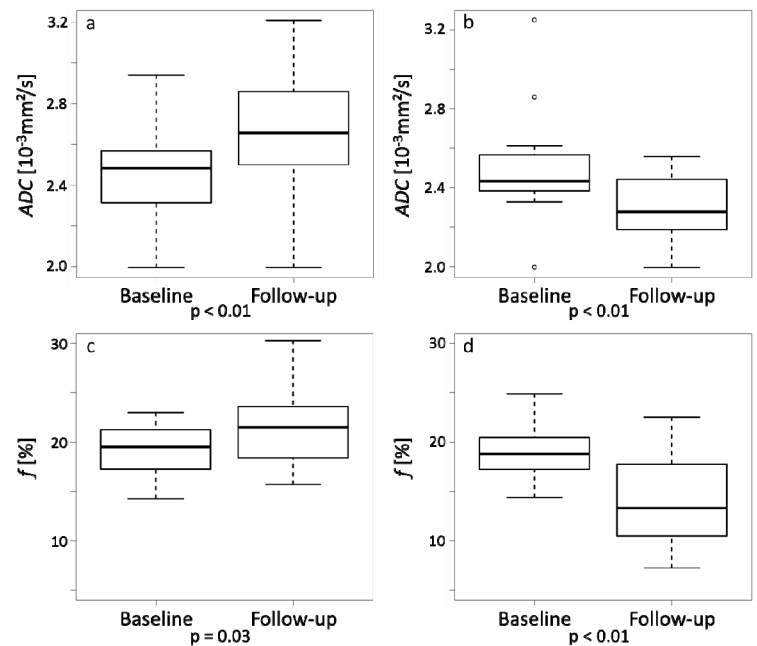


Figure 1: Boxplots of kidney cortex parameters prior to and one week after partial nephrectomy. (a) and (c): ADC and f in non-nephrectomized kidneys; (b) and (d) ADC and f in partially nephrectomized kidneys.