

MR Physics & Techniques for Clinicians: Spin Echo Imaging

Pauline Wong Worters, PhD
GE Healthcare (pauline.worters@ge.com)

Objectives

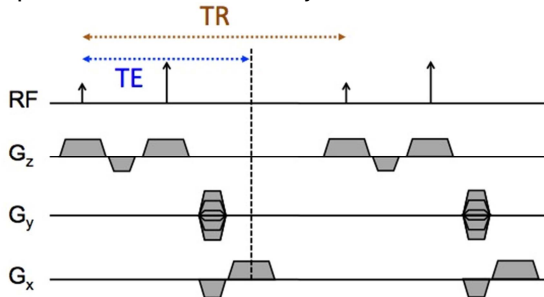
- Understand the basic physics and properties of pulse sequences based upon spin echoes
- Describe fast spin-echo imaging and applications of basic MR pulse sequences
- Design MRI protocols for diagnostic applications considering image contrast, spatial resolution, acquisition time, signal-to-noise ratio and artifacts

The Spin Echo

Spin echo imaging is often called the workhorse of MRI as it is frequently a large part of many clinical protocols. By definition, the “spin echo” is the *occurrence of transverse magnetization that has been re-phased by a refocusing RF pulse*. Note that transverse magnetization exists following an excitation RF pulse that tips the magnetization from the equilibrium, longitudinal direction into the transverse plane. The spin echo effect was explained by Erwin Hahn in 1950 [1], and further developed by Carr and Purcell who pointed out the advantages of using a 180° refocusing RF pulse for the second pulse [2]. Another improvement was made by Meiboom and Gill in orientating the axes of the excitation and refocusing RF pulses perpendicular to each other [3]. These two improvements give rise to the term “CPMG condition”.

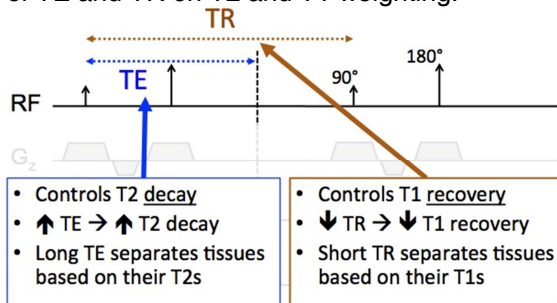
The figure below shows the spin echo pulse sequence, which illustrates a couple of important parameters when describing the pulse sequence:

- TE:** time to echo from the excitation RF pulse
- TR:** repetition time between adjacent excitation RF pulses



Imaging Contrasts

Generation of contrast in SE imaging sequences is primarily controlled by the TE and TR. Figure below describes the effect of TE and TR on T2 and T1 weighting.

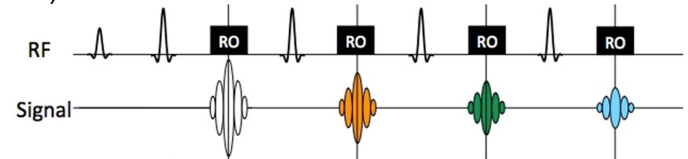


Additional image contrasts generated using Inversion Recovery (e.g., STIR and FLAIR) and Fat Saturation will be covered in the lecture.

Acceleration with Fast Spin Echo

Spin Echo acquisitions are often lengthy, especially in non-interleaved 2D and 3D acquisitions, due to the long TR and therefore “dead” time.

Rapid Acquisition with Relaxation Enhancement (RARE [4], a.k.a Fast Spin Echo, FSE and Turbo Spin Echo, TSE) was developed to accelerate the SE sequence by having a train of multiple refocusing RF pulses (and hence echoes) following a single excitation RF pulse (see figure below for an example of an FSE with a turbo-factor/echo-train-length = 4).



The additional readout (RO) echoes are put in place where there would otherwise have been dead time. These additional echoes acquire k-space data and effectively shorten the acquisition time.

Image Artifacts

Some common image artifacts seen in Fast Spin Echo imaging include image blurring of long T2 species and Magnetization Transfer (MT) saturation. These will be covered in the lecture.

Comparison with Gradient Echo imaging

Spin Echo	Gradient Echo
T2 weighted	T2* weighted
Relatively high SAR	Relatively low SAR
Typical TE: 10-100s ms	Typical TE: 1-4 ms
Typical TR: 10-1000s ms	Typical TR: 3-10s ms
Resistant to susceptibility-induced intra-voxel de-phasing or signal void	Susceptible to susceptibility-induced intra-voxel de-phasing or signal void
Echo-train form: RARE / FSE / TSE	Echo-train form: EPI

References

- [1] Hahn EL. Spin Echoes. Phys Rev 1950;80:580-594.
- [2] Carr HY, Purcell EM. Effects of Diffusion on Free Precession in Nuclear Magnetic Resonance Experiments. Phys Rev 1954;94:630-638.
- [3] Meiboom S, Gill D. Modified Spin-Echo Method for Measuring Nuclear Relaxation Times. Rev Sci Instrum 1958;29:688-691.
- [4] Hennig J, Nauerth A, Friedburg H. RARE Imaging: a Fast Imaging Method for Clinical MR. Magn Reson Med 1986;3:823-833.