

In vivo Diffusion MRI at 7 Tesla

Robin M. Heidemann, PhD robin.heidemann@siemens.com

HIGHLIGHTS

- Ultra-high field MRI yields unprecedented spatial resolution for applications such as structural and functional MRI.
- It is argued that diffusion MRI (dMRI) benefits from ultra-high field strength.
- More advanced acquisition and reconstruction strategies are necessary, to benefit from the higher SNR at ultra-high field strength for in vivo dMRI.

TARGET AUDIENCE – “Neuroscientists looking to investigate the human brain in vivo with ultra-high resolution dMRI at 7 Tesla.”

OUTCOME/OBJECTIVES – “Participants will get an overview of ultra-high field (UHF, 7T and above) specific problems related to the use of diffusion-weighted echo planar imaging (EPI). Advanced EPI strategies will be reviewed, which can be used to address these issues. It will be demonstrated that these strategies make it possible to benefit from the SNR gain associated with the higher field strength in diffusion MRI (dMRI).”

PURPOSE – “Commonly in dMRI image voxels of about 3 mm in each dimension are used. The main reasons for this low spatial resolution are the need for a short EPI readout time and a short echo-spacing. Shortening these two parameters results in reduced EPI distortions, reduced image blurring and in an increased signal-to-noise ratio (SNR). Since the SNR is proportional to the voxel volume, the SNR reduction due to a higher in-plane resolution is sometimes compensated by an increased slice thickness. However, anisotropic voxels can be problematic if a complex and convoluted object such as the human brain is investigated. Partial volume effects will affect tracking results and lead to false FA values (see Fig. 1). In general, a high isotropic spatial resolution is vitally important for dMRI to investigate the human brain in vivo.”

METHODS – “Hardware developments such as ultra-high field scanners and high performance gradient systems can be used to acquire ultra-high resolution dMRI data. However, unwanted effects, such as susceptibility artifacts and image blurring scale with field strength. To benefit from the SNR gain due to the higher field strength, it is necessary to use more advanced acquisition strategies addressing these effects. Image quality in dMRI mainly depends on a short echo time and a short echo spacing. So, most EPI strategies target on reducing the data readout and the diffusion encoding time.”

RESULTS – “The higher SNR associated with the higher field strength can be used to achieve a nominal isotropic sub-millimeter resolution for human in vivo dMRI at 7T.”

DISCUSSION – “The main reason for moving towards ultra-high field strength is an associated increase in SNR. In general, the higher SNR can be used to achieve a higher resolution for certain applications. Advanced EPI strategies are necessary to benefit from the increased SNR for human in vivo dMRI. Isotropic millimeter and even sub-millimeter resolution is feasible at 7T with a sufficiently high SNR to resolve crossing fibers.”

CONCLUSION – “The resulting high resolution diffusion MRI data will permit detailed studies of neuroanatomical structures in the human brain in vivo (see Fig. 2). New insight into Neurological processes in the living human brain will be gained in future studies.”

SOME REFERENCES

1. Robin M. Heidemann, David A. Porter, Alfred Anwander, Thorsten Feiweier, Keith Heberlein, Thomas R. Knösche, Robert Turner. Diffusion Imaging in Humans at 7T using Readout-Segmented EPI and GRAPPA. *Magn Reson Med* 2010 Jul; 64(1):9-14.
2. Cornelius von Morze, Douglas A.C. Kelley, Timothy M. Shepherd, Suchandrima Banerjee, Duan Xu, Christopher P. Hess. Reduced Field of View Diffusion Weighted Imaging of the Brain at 7T. *Magn Reson Imaging* 2010 Dec; 28(10): 1541–1545.
3. Robin M. Heidemann, Alfred Anwander, Thorsten Feiweier, Thomas R. Knösche, Robert Turner. k-space and q-space: Combining ultra-high spatial and angular resolution in diffusion imaging using ZOOPPA at 7T. *NeuroImage* 2012 Apr; 60(2):967–978.
4. Ha-Kyu Jeong, John C. Gore and Adam W. Anderson. High-resolution human diffusion tensor imaging using 2-D navigated multishot SENSE EPI at 7 T. *Magn Reson Med* 2013 Mar; 69(3):793–802.
5. Christopher J. Wargo, John C. Gore. Localized high-resolution DTI of the human midbrain using single-shot EPI, parallel imaging, and outer-volume suppression at 7 T. *Magn Reson Imaging* 2013 Jul; 31(6), 810-819.
6. Cornelius Eichner, Kawin Setsompop, Peter J. Koopmans, Ralf Lützkendorf, David G. Norris, Robert Turner, Lawrence L. Wald, Robin M. Heidemann. Slice Accelerated Diffusion-Weighted Imaging at Ultra-High Field Strength. *Magn Reson Med* 2013 Jun; online first DOI: 10.1002/mrm.24809.

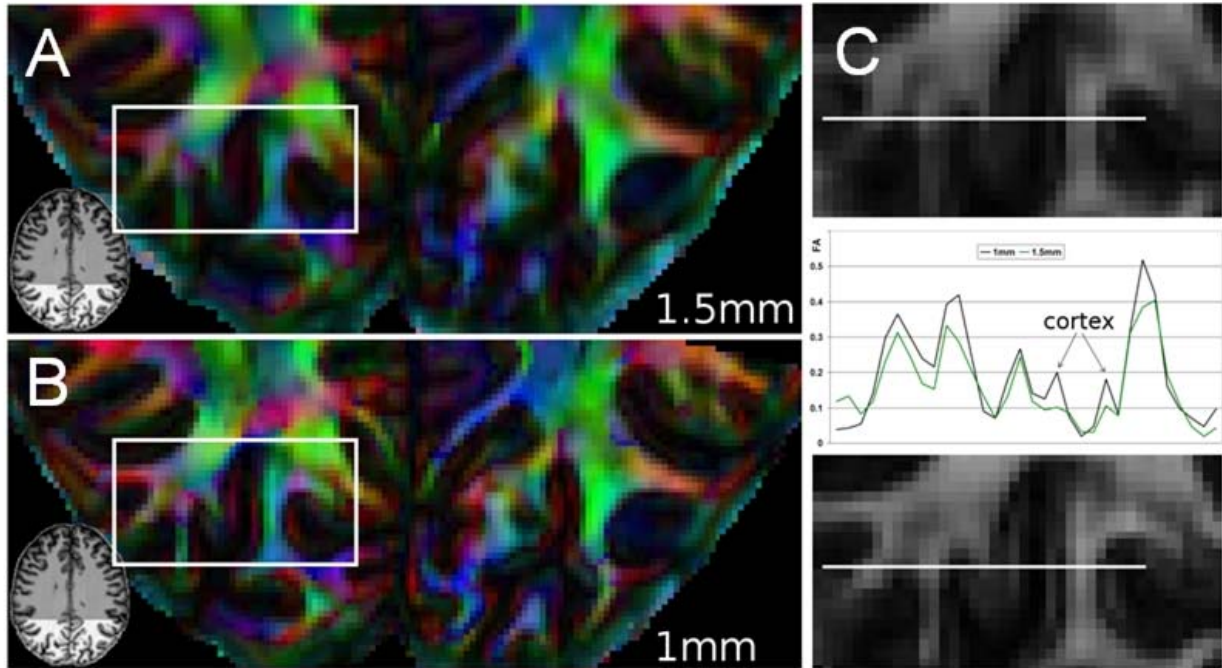


Fig. 1: Comparison between different resolutions: (A and B) Sections of an axial color coded directional map with 1.5 mm isotropic resolution (A) and with 1.0 mm isotropic resolution (B). (C) Corresponding enlarged sections, as indicated by the white boxes in (A) and (B), showing the fractional anisotropy values. Profiles, indicated by white lines are plotted in the middle of (C).

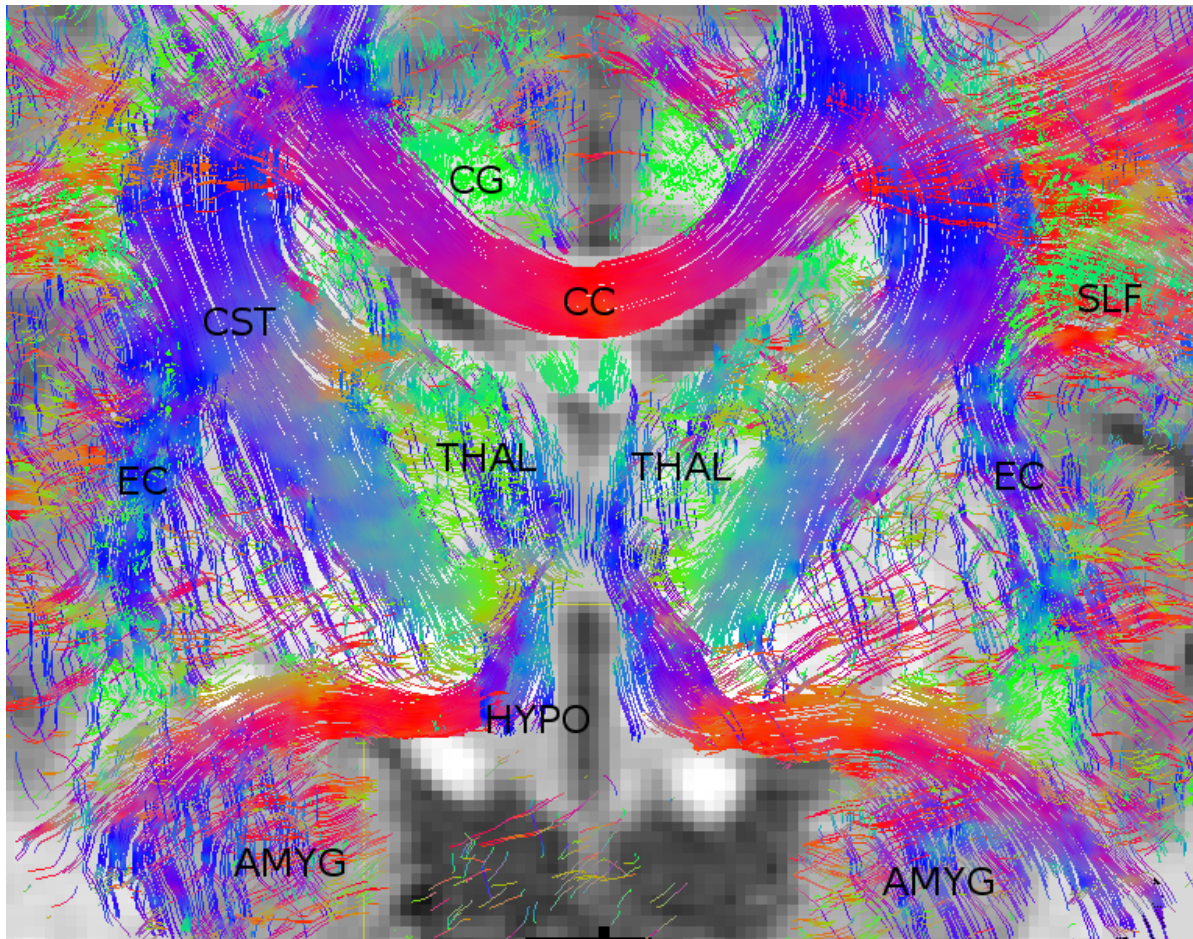


Fig. 2: Sub-millimeter isotropic resolution dMRI: Coronal ZOOMPA DW EPI acquisition with 800 μm isotropic resolution (all tracks in a slab of 2 mm): k-space: massive bundle connecting amygdala (AMYG) with the hypothalamus (HYPO). q-space: crossing of the corpus callosum (CC) with the cortico-spinal tract (CST) and the superior longitudinal fasciculus (SLF). Fibers within the amygdala (AMYG) and the thalamus (THAL) are reconstructed.