

Segmentation methods and lesion masking influence spatial normalization and the detection of task-related activity. On behalf of the HERMES Study Group

Marie-Charlotte Plichta¹, Agnes Aghetti², Thomas A Zeffiro³, Laurent Lamalle^{4,5}, Olivier Detante^{6,7}, Marc Hommel⁸, and Assia JAILLARD^{5,9}
¹CHU Grenoble, Grenoble, France, ²Centre Hospitalo Universitaire, Grenoble, France, ³Neural Systems Group, Massachusetts General Hospital, Boston, Massachusetts, United States, ⁴Unité IRM 3T - Recherche, Centre Hospitalo Universitaire, Grenoble, France, ⁵IRMaGe — Inserm US 17 / CNRS UMS 3552 RMN biomédicale et Neurosciences, SFR de l'Université Joseph Fourier, Grenoble, France, ⁶Stroke Unit, Centre Hospitalo Universitaire, Grenoble, France, ⁷Equipe 5 : Neuroimagerie Fonctionnelle et Perfusion cérébrale, Grenoble Institut des Neurosciences (GIN) Inserm U 836, Grenoble, France, ⁸CIC Pôle Recherche, Centre Hospitalo Universitaire, Grenoble, France, ⁹Unité IRM 3T Recherche. Pôle Recherche., Centre Hospitalo Universitaire, Grenoble, France

Target

Physicians and scientists doing clinical neuroimaging research in patients with brain lesions. We assessed the effects of segmentation methods and mask application on the quality of MRI spatial normalization of brains and the subsequent fMRI task-related activation in stroke patients with large lesions.

Purpose

Functional MRI (fMRI), by examining neural reorganization associated with stroke recovery, provides biomarkers useful in assessing new treatments in small stroke samples. Establishing specific roles for fMRI biomarkers requires sensitive, specific and efficient preprocessing methods, among which tissue segmentation remains a crucial processing step that may alter subsequent spatial normalization accuracy. Segmentation of brains with large lesions involves tissue components whose intensity characteristics often differ from normal brain tissue. The way the segmentation is performed and whether the stroke lesion should include a lesion mask to facilitate segmentation remain to be determined.^{1, 2} A related question is about the size of the mask, i.e. the necrotic tissue or the whole extent of ischemic tissue. This study compared the combined effects of using two different segmentation methods and two different lesion masks in an SPM8 preprocessing stream.

Methods

Segmentation methods were assessed in 19 consecutive patients with a large stroke lesion from an ongoing study assessing stem cell therapy using fMRI (Achieva 3.0T Philips) in stroke patients (ISIS-HERMES <http://clinicaltrials.gov/ct2/show/NCT00875654>). To assess the effect of mask extent and different segmentation methods, we proceeded using a two-step approach.

Mask specification: Two masks were manually delineated from T1 and 3-D FLAIR sequences (Voxel (mm) = 1x1x1; no gap) using MRICron (<http://www.nitrc.org/projects/mricron>). Mask-1 included the necrotic part and mask-2 the whole stroke lesion.

Segmentation using two different methods from SPM8: In Method-1, segmentation (Segment) was based on the use of 3 TPMs (tissue probability maps) including grey matter, white matter and CSF. In Method-2, segmentation (New Segment) based on the use of 6 tissue probability maps were used.

Then we compared the six resulting normalized T1 images (no mask; necrotic mask; whole mask / Segment or New Segment), and the corresponding fMRI activation maps using the six different spatial normalizations at $p(\text{uncorrected}) < 0.001$.

Results

The normalized T1 images were altered after segment method-1, with brain tissue observed outside of the MNI template in 14/19 patients. The application of a mask did not correct this problem. New Segment method-2 led to satisfactory T1 normalized images in all patients. No significant difference was observed between masks and no mask.

Method-1: There was related tactile sensory activity at the group level in the contralesional somatosensory cortex level. Using a mask did not modify the results (Fig.1).

Method-2: Tactile stimulation was associated with ipsilesional sensorimotor cortex activity at the group level using the necrotic mask or no mask, while only the ipsilesional somatosensory cortex was activated using the whole lesion mask (Fig.1).

Discussion

We showed that, in the presence of large brain lesions, different T1 image segmentation methods influence spatial normalization, affecting the detection of task-related activity at the group level. Although using a lesion mask did not completely correct the altered brain normalization, its use may increase the quality of the results.

Conclusion

Tissue segmentation and spatial normalization in patients with large focal lesions appears to be crucial steps in fMRI data analysis. The use of a lesion mask may be useful but not a sufficient step to ensure accurate spatial normalization.

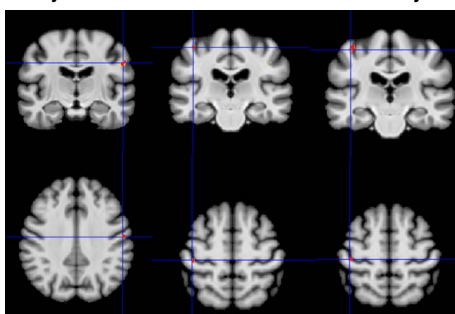


Figure 1 showing different peak tactile task-related activations for the right impaired hand according to the preprocessing method: right somatosensory cortex for Segment and left somatosensory cortex for New-Segment. The stroke lesion is located in the left hemisphere, corresponding to on the left side of the picture.

References

1. Crinion J, Ashburner J, Leff A, Brett M, Price C, Friston K. Spatial normalization of lesioned brains: Performance evaluation and impact on tmri analyses. *Neuroimage*. 2007;37:866-875
2. Andersen SM, Rapcsak Z, Beeson M. Cost function masking during normalization of brains with focal lesions: Still a necessity? *Neuroimage*. 2010;53:78-84