

Effects of pre-reperfusion NBO administration in experimental ischemic stroke

Yash Vardhan Tiwari¹, Yuhao Sun¹, Fang Du¹, Qiang Shen¹, and Timothy Q Duong¹

¹Research Imaging Institute, University of Texas Health Science Center San Antonio, San Antonio, Texas, United States

Target audience: Researchers in stroke, oxygen therapy and neuroprotection.

Purpose: Normobaric hyperoxia (NBO) has shown to improve and worsen stroke outcomes in ischemic stroke¹. The positive outcome of NBO treatment in cerebral ischemia may depend on treatment window and treatment duration which remains less explored. The goal of this study was to use quantitative MRI to longitudinally evaluate the effects of NBO in early pre-reperfusion treatment window (60 & 90 min reperfusion post MCAO) with varying NBO treatment duration (25 min & 50 min respectively).

Methods: Twenty-three male SD rats (250-300g) were subjected to 60-min MCAO and 90-min MCAO followed by reperfusion. In a randomized and double-blinded experimental design, animal groups received NBO treatment or air (control). NBO was administered from 30-55 min in the 60-min MCAO group and 30-80 min in the 90-min MCAO group. Each experimental group had 6 rats except the NBO treatment group of the 60-min MCAO (n=5).

Quantitative CBF, ADC and T2 maps were acquired at 7T and analyzed as described elsewhere². Initial lesion volume was defined by ADC lesion at 30 minutes. Edema corrected final lesion volumes were derived from 48hr T2 maps and percent change in lesion volume was calculated for all animals.

Paired t-test was used for comparison between initial lesion and final lesion within group and unpaired t-test was used for comparison between groups. A P-value of 0.05 was taken to be statistically significant. Data shown in figures and texts are group averaged mean \pm SEM.

Results: For the 60 min MCAO study, the initial ADC defined lesion volumes at 30 min post MCAO which were acquired before treatment were not statistically different. The air treated group showed an increase of $15 \pm 4.3\%$ ($P < 0.05$) in lesion volume at 48hr after stroke whereas the NBO treated group showed a smaller increase of $5.6 \pm 1.8\%$ ($P = 0.16$) in lesion volume at 48hr after stroke (**Figure 1**).

For the 90 min MCAO study, the initial ADC defined lesion volumes at 30 min post MCAO which were acquired before treatment were not statistically different. The initial lesion volume at 30 min increased by $24.5 \pm 9.6\%$ ($P < 0.05$) at 48hr in the air treated group, but decreased by $10.7 \pm 3\%$ ($P < 0.05$) in the NBO treated group at 48hr after stroke. The NBO-treated lesion volume was significantly smaller than air-treated lesion volume at day 2 by 35.2% ($P < 0.05$) (**Figure 2**).

Discussion and Conclusions: In the air treated group, the 48hr lesion volume of the 90-min MCAO group was only slightly larger than the 60-min MCAO group, quantitatively similar those reported previously by our group³. NBO treatment decreased lesion volumes in both MCAO groups compared to the corresponding air treatment groups. The 48hr lesion volume of the 60-min MCAO group grew slightly whereas that of the 90-min MCAO group decreased, resulting in the 90-min MCAO group having smaller lesion volume than the 60-min MCAO group with NBO treatment. A likely explanation is that the NBO treatment in the 60-min MCAO group, although effective, was short termed. We conclude that NBO treatment along with reperfusion treatment reversed ADC lesion and salvaged tissue, and that longer treatment up to 50 min was more effective. We showed that NBO can not only “buy” time and expand the treatment time window, but also that in pre reperfusion treatment window longer NBO treatment duration further salvages more tissues. Future studies will need to evaluate varying and longer treatment durations. MRI offers a unique and sensitive means to longitudinally monitor and optimize NBO treatment. NBO is cost effective and can be readily administered by emergency responders onsite.

Reference: [1] Qi et al, Med Gas Res 2013;3:2 [2] Shen et al. JCBFM 2004;24:280. [3] Shen et al. ISMRM 2013;2922.

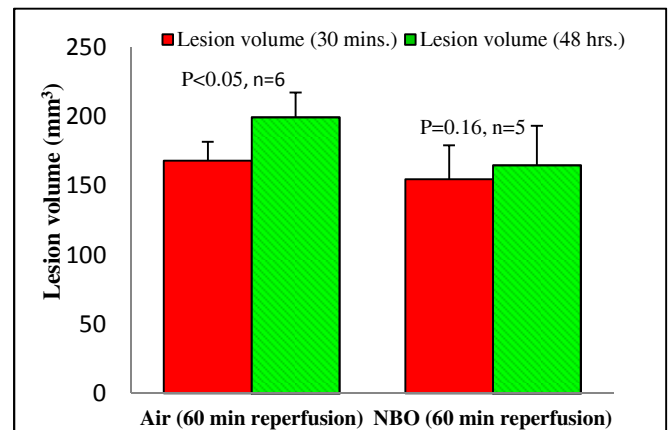


Fig 1 Progression of lesion volume in 60 min reperfusion group (NBO treatment = 25 min)

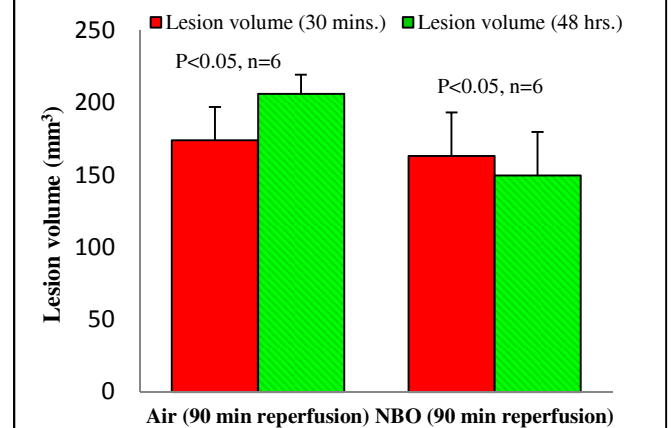


Fig 2 Progression of lesion volume in 90 min reperfusion group (NBO treatment = 50 min)