

Clinical values of IFIR 4D MRA in evaluation of cerebral arteriovenous malformation

Akira Kunimatsu¹, Yasushi Watanabe², Naoyuki Takei³, Masaki Katsura¹, Harushi Mori¹, and Kuni Ohtomo¹

¹Department of Radiology, The University of Tokyo, Tokyo, Japan, ²Department of Radiology, The University of Tokyo Hospital, Tokyo, Japan, ³Global MR Applications and Workflow, GE Healthcare, Japan

Introduction

Since the concept of nephrogenic systemic fibrosis is widely accepted, there has been an increasing demand for non-contrast MRA. However, contrast-enhanced MRA is still standard for time-resolved MRA that is frequently used in some certain diseases including cerebral arteriovenous malformation (AVM). Arterial spin labeling (ASL)-based MRA technique has been introduced to the clinical field and may be an alternative to contrast-enhanced time-resolved MRA in evaluating hemodynamic alteration in cerebral AVM. Inflow enhanced inversion recovery (IFIR) is an ASL-based non-contrast MRA technique [1] that can be implemented into time resolved MRA with a high spatio-temporal resolution (IFIR 4D MRA). IFIR 4D MRA may provide both morphometric and hemodynamic information. To our knowledge, however, the utility of the technique in clinical settings has not been well determined.

The purpose of this study was to determine the clinical utility of IFIR 4D MRA incorporated in routine MRI evaluation of patients with cerebral AVM.

Methods

Patient demographics

IRB at our hospital approved this study. Eight patients with cerebral AVM (2 male and 6 female patients, aged 28 to 65 years, mean 37.7 years) were recruited. Four of the patients underwent non-contrast MRA only, including (A) IFIR 4D MRA and (B) 3D time-of-flight (TOF) MRA. The other four patients underwent (C) contrast-enhanced time resolved MRA in addition to non-contrast IFIR 4D MRA and 3D TOF MRA on the same day.

Three of the patients had not undergone any surgical treatment or radiation therapy for AVM before their participation in this study. The other five patients had been treated with gamma-knife radiosurgery 6 months to 9.5 years before their participation.

Methods for MR imaging

A 3-T clinical scanner (GE Signa HDxt) was used. (A) SPGR-based IFIR 4D MRA data were acquired at every 50 ms, using a Look and Locker acquisition scheme, from 80 to 780 ms after labeling with a flow-sensitive alternating inversion recovery technique (TR/TE= 3.3/1.2 ms, FA = 3, FOV = 22 cm, slice thickness/interslice gap = 1.4/0.7, matrix = 224x160, reconstructed voxel size = 0.4x0.4x0.7 mm) (Fig. 1). (B) 3D TOF MRA data, implemented with a magnetization transfer saturation pulse, were acquired (TR/TE= 26/2.8 ms, FA = 20, FOV = 20 cm, slice thickness/interslice gap = 0.8/0.4, matrix = 512x256, reconstructed voxel size = 0.4x0.4x0.4 mm and (C) contrast-enhanced time-resolved MRA was performed with a time-resolved imaging of contrast kinetics (TRICKS) technique (TR/TE= 4.3/1.5 ms, FA = 20, FOV = 24 cm, slice thickness/interslice gap = 8.0/4.0, matrix = 384x256, reconstructed voxel size = 0.5x0.5x4.0 mm, temporal resolution = 0.8s/frame).

Analyses

Cerebral AVMs were assessed on both morphometric and hemodynamic information. Two readers classified the cerebral AVMs according to Spetzler-Martin grading (deep drainage, eloquent location, and size of the nidus), number of feeding arteries and draining veins, on a consensus basis. Readers also evaluated whether the sequence of draining veins could be distinguished and counted the number of image frames between the image frame where a feeding artery appeared and the same or later frame where a draining vein first appeared.

(A) IFIR 4D MRA and (B) 3D TOF MRA were compared in morphometric analyses. For hemodynamic analyses, comparisons were made between (A) and (C) contrast-enhanced MRA with a TRICKS technique. We used Kendall's W coefficient of concordance for these comparisons. Coefficients of 0.5-0.8 were considered good agreement and above 0.8, excellent agreement [2]. Ability to sequentially discriminate between arterial and venous flow was compared between (A) and (C) by using Wilcoxon's signed rank test. Statistical significance was set at $P = 0.05$.

Results

Excellent concordance was found on the total Spetzler-Martin score between (A) and (B) (Kendall $W = 0.89$). Between (A) and (C), the number of feeding arteries showed excellent concordance (Kendall $W = 0.90$), and that of draining veins showed good concordance (Kendall $W = 0.50$). The mean number of image frames between the appearance of a feeding artery and that of a draining vein was calculated at 6.5 on (A) and 0.8 on (C) respectively, but no statistical significance was found ($P = 0.18$).

Conclusion

Non-contrast IFIR 4D MRA has a sufficient spatial resolution that may have an equivalent ability to that of 3D TOF MRA in elucidating morphometric information of cerebral AVMs. It can provide a higher temporal resolution also than that of contrast-enhanced time-resolved MRA. In clinical practices, IFIR 4D MRA could support morphometric information obtained by 3D TOF MRA and could feasibly add hemodynamic information to 3D TOF MRA, instead of contrast-enhanced time-resolved MRA. IFIR 4D MRA may have certain clinical utility in evaluation of cerebral AVM.

References 1. Takei N, et. al. JMRI 2012 35: 957-62. 2. Illies T, et. al. AJNR 2013 34: 46-53

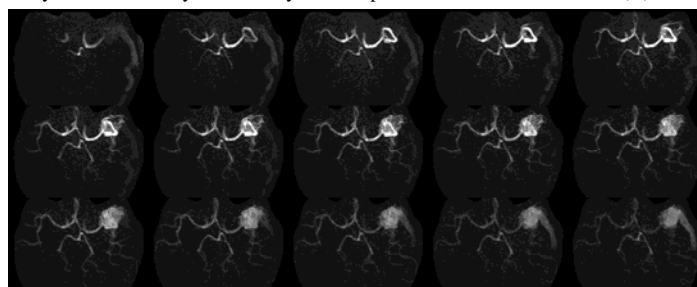


Fig. 1 An example of IFIR 4D MRA in a patient with cerebral AVM 4D MRA images obtained at every 50 ms are sequentially shown from left to right and top to bottom. These allow us to discriminate between feeding arteries and draining veins more easily than contrast enhanced time-resolved MRA.