

Global Effect of Focal Ischemic Stroke Revealed by Regional Homogeneity with BOLD fMRI

Lijuan Zhang¹, Xiaojing Long¹, Yanjun Diao¹, Li Yi², and Chunxiang Jiang¹

¹SIAT, Chinese Academy of Sciences, Shenzhen, Guangdong, China, ²Neurology, Peking University Shenzhen Hospital, Guangdong, China

Introduction

Regional remote effect has been reported in scenarios of ischemic stroke (IS) [1, 2]. The global disturbance of brain function following IS remains to be characterized. This study aims to investigate the functional synchronization at a global level in brains with focal IS lesions using blood oxygen level dependent (BOLD) functional MRI.

Materials and experiments

The study was approved by local institutional review board. Informed consent was obtained from each of the participants prior to the study. A total of 27 patients (22male/5female, aged 38-83years; averaged 60.0±13.3 years) with initial attack of a unilateral focal ischemic lesion in basal ganglia (n=7), corona radiate (n=11) and pons (n=9) were recruited. Magnetic resonance imaging was conducted from 13 to 96 hours (averaged 60.8±40.1h) post onset of the IS on a Siemens Avanto 1.5T system (Erlangen, Germany) with a standard head coil. T1 weighted image (T1WI) was acquired using MPRAGE sequence with TE/TR 3.37ms/1900ms, TI 1100ms, FA 15°, thickness 1mm, and in plane resolution 0.5mm×0.5mm×1mm to provide anatomical references. In addition, diffusion weighted imaging were obtained for the purposes of locating the IS lesion and excluding subjects with unspecific white matter diseases. BOLD fMRI was achieved using a T2*-weighted gradient-echo pulse sequence, with TE/TR 30ms/3000ms, FA 90°, thickness 3mm, in plane resolution 1.56mm×1.56mm×3.75mm, slices 32, and volumes 60. Images were pre-processed using DPARSF (<http://www.restfmri.net/forum/DPARSF>) with slice timing correction, realignment, T1WI-BOLD co-registration, T1WI segmentation and normalization to MNI space, followed by the removal of linear trend and filtering with a bandpass range between 0.01-0.08Hz. The Kendall's coefficient concordance was calculated in each voxel as the region homogeneity (ReHo) value. Smoothing and zero calibration were finally performed on each ReHo map before conducting the group-wise one sample t test. P<0.05 with a cluster size >85 was considered as statistically significant. Statistical images were overlapped to the T1WI to facilitate visual inspection.

Results

Relative to the global mean, increased ReHo (Warm color in Figure) were mainly identified in bilateral visual-auditory cortices, posterior cingulum cortex, cerebellum and middle and inferior frontal gyri in patients with IS lesion in the corona radiate and basal ganglia (Figure, a and b), and to a lesser extent in patients with IS lesion in pons (Figure, c and d). Extensive reduction in ReHo (Cold color in Figure) was detected in brain areas associating with all lobes with a sparsely distribution in brains with IS lesion in pons.

Discussion

Focal IS lesion may trigger diaschisis - functional disturbance through reducing the afferent input, blood and oxygen supply and/or the associated electrophysiological activity [3,4] in remote neural regions that are directly connected with the lesion. However, extensive alteration in the functional synchronization was detected beyond the classical scope [5] of neuronal connection, suggesting that a subtle but global pathophysiological changes was triggered following a focal ischemic attack. Biomedical environment, release of nitrogen monoxide by astrocyte and the level of neurotransmitter may contribute to the variation of cerebral functional integrity in the context of IS. However, the clinical relevance of the altered regional homogeneity is not well understood.

Conclusion

Global alteration of the functional synchronization was observed in brains with typical IS lesions in this study. The varied regional homogeneity may indicate a disintegrative dynamic of the functional homeostasis of the brain under the ischemic injury. Rebalance of the functional synchronization at a global level may provide valuable reference for disease management and rehabilitation of IS.

References

1. Dani KA, et al. *J Cereb Blood Flow Metab* 2012; 32: 211402117.
2. Brodtmann A, et al. *Stroke* 2007; 38: 2360-2363.
3. Madai VI, et al. *J Cereb Blood Flow Metab* 2011; 31: 1439-1500.
4. Wise RJS, et al. Serial observations on the pathophysiology of acute stroke. *Brain* 1983; 106: 197-222.
5. Von Monakov C, Harris G. *Brain and Behavior I: Modes, States and Mind*. Baltimore, Penguin Books 1969; pp 27-36.

Acknowledgement (JCYJ20120615124706404; NSFC81371359)

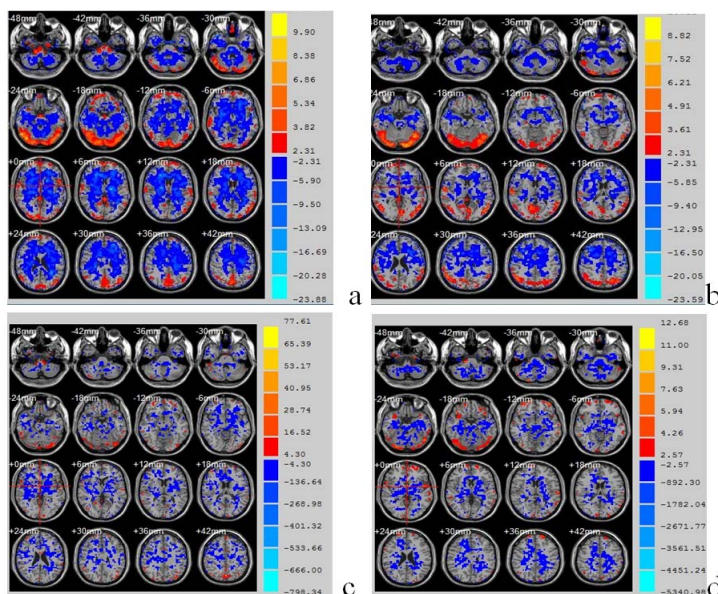


Figure. Results of the one sample t test of ReHo for patients with unilateral IS lesion in left (a) or right (b) corona radiate and basal ganglia, and in left (c) or right (d) pons. Color bar indicates t value.