

ASSESSING BRAIN SYSTEM DYSFUNCTION IN AMNESIC MILD COGNITIVE IMPAIRMENT THROUGH MRI-BASED CONNECTOMICS

Federica Agosta¹, Elisa Canu¹, Sebastiano Galantucci¹, Alessandro Meani¹, Giuseppe Magnani², Alessandra Marcone³, Andrea Falini⁴, Giancarlo Comi², and Massimo Filippi¹

¹Neuroimaging Research Unit, Institute of Experimental Neurology, San Raffaele Scientific Institute, Vita-Salute San Raffaele University, Milan, MI, Italy, ²Department of Neurology, San Raffaele Scientific Institute, Vita-Salute San Raffaele University, Milan, MI, Italy, ³Department of Clinical Neurosciences, San Raffaele Scientific Institute, Vita-Salute San Raffaele University, Milan, MI, Italy, ⁴Department of Neuroradiology, San Raffaele Scientific Institute, Vita-Salute San Raffaele University, Milan, MI, Italy

Target audience. Neurologists and neuroradiologists.

Purpose. Brain networks supporting complex cognitive processes are specifically and progressively impaired over the course of Alzheimer's disease (AD).¹ Brain connectomics may be sensitive to early network changes in amnesic mild cognitive impairment (aMCI).² This study investigated the topological organization of functional brain network connectivity in patients with aMCI.³

Methods. Graph theoretical analysis was applied to resting state functional MRI data from 45 aMCI patients and 32 age-matched healthy controls. Functional connectivity between 90 cortical and subcortical brain regions was estimated using bivariate correlation analysis and thresholded to construct a set of undirected graphs. Measures of global and local network organization were obtained.

Results. Small-worldness was verified in patients and controls. Functional brain networks in aMCI patients were characterized by a significantly higher hierarchy compared with healthy subjects. Compared to controls, aMCI patients did not show hub regions in the right hippocampus, anterior cingulate and calcarine cortices bilaterally, and left putamen and caudate nucleus (Figure A). Compared with controls, aMCI patients showed a pattern of increased betweenness centrality in the posterior cingulate cortex bilaterally, left angular, inferior parietal and supramarginal gyri, and right superior medial frontal cortex (Figure B).

Discussion and conclusions. The global organization of functional networks is relatively preserved in aMCI patients, except for an increased hierarchy of the brain functional networks. High hierarchy suggests a high sub-modular decomposition of the functional networks, which is thought to be negatively related with the span of control acted by the central module. On the contrary, local functional network organization is altered in aMCI patients showing a loss of major hubs in the regions typically hit by the disease and evidence for increased connectivity locally within the parietal and frontal lobes. Graph analysis provides additional insights into the physiology of early changes in Alzheimer's disease.

References. 1. Xie T, He Y. *Front Psychiatry* 2012;2:77. 2. Bullmore E, Sporns O. *Nat Rev Neurosci* 2009;10:186-98; 3. Albert MS, et al. *Alzheimers Dement* 2011;7:270-9.

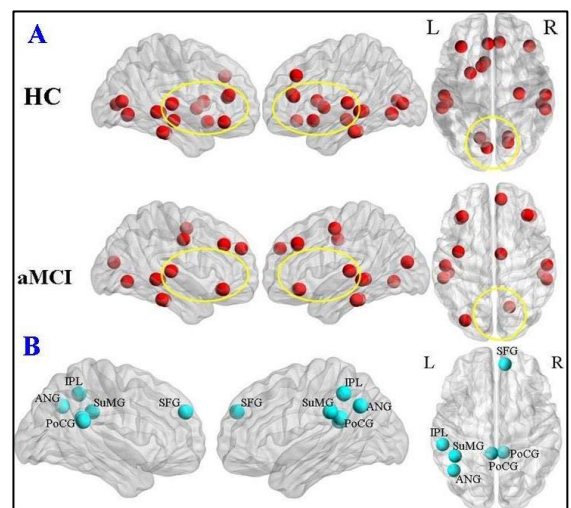


Figure. [A] Cortical hubs in aMCI patients and healthy controls (HC) are shown in red. [B] Regions of higher betweenness centrality in aMCI patients vs HC are shown in cyan.