

Direct Comparison of Integrated PET-MRI and PET-CT FDG Quantification in the Dementia Population

Timothy Shepherd¹, Bang-Bin Chen², Kent Friedman¹, Christopher Glielmi³, Thomas Koesters¹, Kimberly Jackson¹, Yu-Shin Ding¹, David Faul³, and Fernando Boada¹
¹Bernard and Irene Schwartz Center for Biomedical Imaging, Department of Radiology, New York University School of Medicine, New York, NY, United States,
²Department of Medical Imaging, National Taiwan University Hospital, Taiwan, ³Siemens Healthcare, New York, NY, United States

TARGET AUDIENCE: Clinicians and researchers interested in clinical implementation and quantitative radiotracer studies using new integrated PET-MRI.

PURPOSE: Simultaneous PET-MRI for patients suspected of neurodegenerative disorders may facilitate shortened examination times, PET coregistration to high-resolution anatomic data, temporally-synchronized data collection and increased diagnostic accuracy. This has enormous potential to improve the clinical workup for this patient population. Research studies also indicate a combination of PET and MRI biomarkers may lead to the most accurate diagnostic staging of patients with Alzheimer's dementia and monitoring their responses to experimental therapies. However, this may require precise quantification of PET radiotracers that depends on accurate attenuation correction (AC). Unlike CT, AC is not trivial in MRI due to the absence of signal in air and bone. To better understand the magnitude of this problem, we compared Dixon and ultrashort echo time (UTE) MRI-based AC methods directly to CT-based AC in dementia patients.

METHODS: Elderly patients with memory complaints and suspected dementia undergoing clinical fluoro-dexoy-glucose (FDG) PET-CT were consented to undergo PET-MRI using an FDA-approved 3-T combined PET/MRI scanner (Biograph mMR, Siemens Healthcare, Erlangen, Germany). PET-CT utilized a 15-minute PET acquisition on a Biograph mCT with iterative reconstruction, 512x512 matrix, 2-mm slice interval and low-dose CT for attenuation correction. PET-MRI were acquired in list-mode for 60 minutes and reconstructed with OSEM, 344x344 matrix, 2-mm slice interval and Dixon or UTE MR-based attenuation correction. CT, MRI and PET data were coregistered and normalized into standardized space (2 mm³) using FSL, and 80 regions-of-interest (ROI) were created from anatomical parcellation based on the Harvard-Oxford atlas.

RESULTS: Sequential brain PET-CT then PET-MRI were obtained from 24 patients (73.6 ± 8.2 yrs old, 9 female) with suspected dementia after a single IV dose of FDG (9.7 ± 0.6 mCi). Mean uptake time for PET-CT and PET-MRI were 61.2 ± 11.5 min and 164.2 ± 36.7 min respectively. Clinical interpretation of studies indicated 8 subjects appeared normal whereas 16 had different severities of AD-pattern FDG hypometabolism (8 mild and 8 moderate/severe). There were minimal differences in clinical FDG pattern interpretation between PET-MRI and PET-CT (Fig. 1). For all brain regions, the mean correlation coefficient between Dixon or UTE-based AC to CT-based AC was 0.963 and 0.955 respectively. The lowest correlation coefficients were noted in the temporal pole for both Dixon (0.905) and UTE (0.885). For all brain regions, the mean SUV underestimation of Dixon or UTE-based AC relative to CT-based AC was 14.9 ± 3.0% and 24.8 ± 3.6%, respectively. The most significant underestimation of SUV for both methods was the anterior fusiform gyrus in the basal temporal lobe.

DISCUSSION: Combined PET-MRI appears feasible and valid for routine clinical workup of patients suspected of dementia. Clinical diagnosis and monitoring in this patient population is moving toward quantitation of uptake of FDG, amyloid and/or tau radiotracers. While radiotracer uptake correlations between PET-CT and PET-MRI were excellent (> 0.9 all comparisons), there is some underestimation of SUV (~15% in Dixon-based AC method). In subjects with the most SUV underestimation on PET-MRI in the anterior fusiform gyrus, there was either swapped tissue and fat compartments for Dixon-based AC maps, or over-estimated extent of air cavities for UTE-based AC maps relative to CT. Underestimation also may be confounded by region-specific pharmacokinetic differences for FDG uptake, retention or dilution during the ~100-min delay between PET-CT and PET-MRI data acquisition in the current study design.

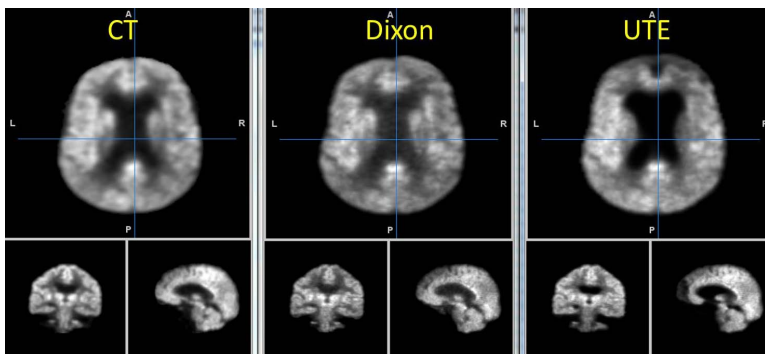


Fig. 1: PET corrected with CT-, Dixon- and UTE-based attenuation correction demonstrate similar uptake patterns.

CONCLUSION: Integrated PET-MRI in patients with suspected dementia demonstrated excellent correlations between MRI-based AC methods and relative "gold-standard" CT-based AC for PET FDG quantification, but with some underestimation of SUV. AC differences between CT and MRI were most pronounced in the basal and anterior temporal brain regions that are surrounded by variably pneumatized bone in the skull base. While these specific brain regions may not be critical to quantifying the impact of AD-pathology indirectly using radiotracer uptake, it is hoped pending modifications to Dixon-based MRI AC will further improve correspondence with CT-based AC.

REFERENCES: 1. Hampel et al. Nature Reviews Drug Discovery 9, 560-574 (July 2010).