

Degeneration of Functional and Structural Connection between the Two Hemispheres in AD and MCI

Jianli Wang¹, Zhiqun Wang², Han Zhang³, Robert Mchugh¹, Xiaoyu Sun¹, Kuncheng Li², and Qing X. Yang^{1,4}

¹Radiology, Penn State College of Medicine, Hershey, PA, United States, ²Radiology, Xuanwu Hospital of Capital Medical University, Beijing, China, ³Center for Cognition and Brain Disorders, Hangzhou Normal University, Hangzhou, Zhejiang, China, ⁴Neurosurgery, Penn State College of Medicine, Hershey, PA, United States

Introduction:

Alzheimer's disease (AD) patients were found to perform poorly on tasks that require interhemispheric communication [1], which suggests a deficit in the interhemispheric integration of information. This is supported by the atrophy of the corpus callosum (CC), the major structure for interhemispheric connectivity, in AD and mild cognitive impairment (MCI) patients [2,3]. Diffusion tensor imaging (DTI) of the CC demonstrated significant changes in fractional anisotropy (FA), mean diffusivity (MD), radial diffusivity (λ_{\perp}), and axial diffusivity (λ_{\parallel}) in early AD and MCI [4,-6]. Yet, the specific relationships between these structural changes and the functional deficits in AD remain to be determined. To address this relationship, we quantitatively measured interhemispheric functional connectivity (FC) using resting-state fMRI (rs-fMRI) and diffusion parameters with DTI in the AD and MCI and compared with those in the cognitive normal healthy controls (CN).

Methods:

Human Subjects: 16 AD (age 71.6±5.9 years, 7 male, Clinical Dementia Rating scale (CDR) 0.8±0.5, Mini-mental State Examination (MMSE) score 18.0±3.4), 16 MCI (age 70.9±7.6 years, 7 male, CDR 0.4±0.2, MMSE score 26.6±1.1), and 16 age/gender-matched CNs (age 69.3±7.8 years, 7 male, CDR 0, MMSE score 28.6±0.7) participated in the study. All AD and MCI patients were clinically diagnosed by the AD specialists in the memory clinic. All subjects gave written informed consent, which was approved by the institutional review board.

Data Acquisition: The MRI studies were carried out on a Siemens Magnetom Trio 3.0 T scanner. rs-fMRI images were acquired using a BOLD sensitive EPI sequence with TR/TE =2000 ms/40 ms and number of repetitions=239. DTI parameters were: 12 non-linear directions (b-value=0, 1000 s/mm²), TR/TE=6000 ms /85 ms, FOV=256 mm×256 mm, acquisition resolution=128×128, 30 axial slices, slice thickness=5 mm, number of averages=4.

Data Processing and Analysis: The rs-fMRI data were processed using SPM8 and DPARSF toolkits [7] following the standard procedure. The interhemispheric FC was analyzed with voxel-mirrored homotopic connectivity (VMHC) method. First, a left-right hemisphere symmetric brain template was generated from the 48 subjects to remove the geometric differences between the two hemispheres. The same left-right geometric transformation was applied to the rs-fMRI images in the MNI space. Then homotopic FC between each pair of symmetric voxels in left-right hemispheres was calculated with a Pearson's correlation and then Fisher-Z transformed. Group comparisons of VMHC were conducted using one-way ANOVA with age and total grey matter volume as the nuisance covariates ($p < 0.01$, corrected using AlphaSim with a cluster size > 97 voxels).

The DTI data were processed following standard procedure with DTI-Studio version 3.0.3. DTI parametric maps (FA, MD, λ_{\parallel} and λ_{\perp}) were estimated from each subject, co-registered to the T1-weighted image by SPM8, normalized to the MNI space with DARTEL. The comparison of each diffusion parameter map among the 3 cohorts was made using one-way ANOVA with intracranial volume correction. Within the genu of the corpus callosum (CC_{genu}), we recorded the mean diffusion parameters of the above-threshold cluster and correlated with age, VMHC, CDR, and MMSE scores using SPSS. Since age is a significant risk factor for AD and correlates with diffusion parameters in normal aging [8], age was used as a confounding factor in the correlation analysis.

Results: The VMHC map in CNs revealed strong interhemisphere connectivity in the brain regions known to be important for cognition, including anterior and posterior cingulate cortex (ACC and PCC), dorsolateral prefrontal cortex (DLPFC), orbitofrontal cortex (OFC), sensorimotor cortex (SMC), parietal and occipital cortices, hippocampus and various temporal cortices, insula, basal ganglia, and thalamus.

Compared to the CNs, the ADs had significantly weaker VMHC in the OFC, ACC, nucleus accumbens (NAcc), primary olfactory cortex, putamen, caudate, and insula (Fig. 1C-E). The ADs also had significantly weaker VMHC than the MCIs in the OFC, putamen, caudate, and insula. Conversely, the MCIs showed significantly stronger VMHC in the SMC than CNs (Fig. 1F). The FA (Fig. 1A,B), MD, and λ_{\perp} maps showed significant degeneration in the CC_{genu} of ADs and MCIs. Significant positive correlations between VMHC in the anterior brain regions (OFC, ACC, and NAcc) and FA value of the CC_{genu} were observed. The FA and volume of the CC_{genu} were positively correlated with MMSE scores. Consistent with the structural connectivity, the VMHC in the OFC, ACC, and NAcc were positively correlated with MMSE scores.

Discussions and Conclusion:

There were significant interhemisphere FC changes in the AD and MCI. The degeneration of CC_{genu} was significantly correlated with the VMHC decline in the ACC, OFC, and NAcc, and with cognitive performance. Increased VMHC observed in the MCI in posterior brain regions may represent a compensation mechanism. The specific patterns of interhemisphere FC changes in the AD and MCI may be an important contributing factor to cognitive impairment present in these disease states.

References:

- Lakmache Y, et al. PNAS, 1998; 95:9042-6.
- Chaim TM, et al. Psychiatry Res, 2007; 154:59-68.
- Wang L, et al. Neuroimage, 2006; 31:496-504.
- Di Paola M, et al. Neurology, 2010; 74:1136-42.
- Preti MG, et al. PLoS One, 2012; 7:e35856.
- Xie S, et al. Neurology, 2006; 66:1845-9.
- Yan C, Zang Y. Front Syst Neurosci, 2010; 4:13.
- Stadlbauer A, et al. Radiology, 2008; 247:179-88.

Acknowledgements:

This study was supported by the NIH, Natural Science Foundation of China, and Beijing Natural Science Foundation.

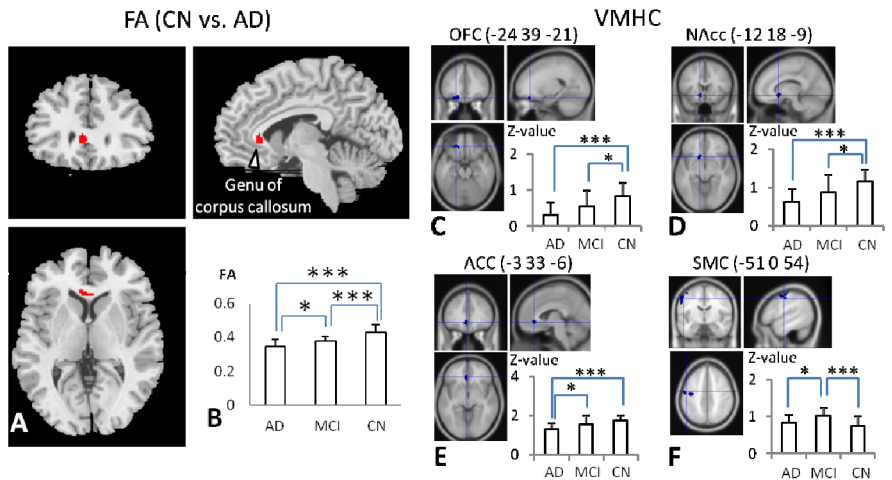


Fig. 1. Comparison of FA in the genu of CC (A,B) and the VMHC (C-F) between AD, MCI, and CN.