

# Oxygenation responses to an autonomic challenge in the elderly estimated with the means of quantitative fMRI. Is the white matter at risk of hypoxic injury?

Iwo Jerzy Bohr<sup>1</sup>, Claire McDonald<sup>2</sup>, Jiabao He<sup>3</sup>, Simon Kerr<sup>4</sup>, Julia Newton<sup>5</sup>, and Andrew M Blamire<sup>1</sup>

<sup>1</sup>Newcastle Magnetic Resonance Centre, Newcastle University, Newcastle upon Tyne, United Kingdom, <sup>2</sup>Newcastle University, United Kingdom, <sup>3</sup>Aberdeen Biomedical Imaging Centre, University of Aberdeen, Aberdeen, United Kingdom, <sup>4</sup>Institute for Ageing and Health, Newcastle University, Newcastle upon Tyne, United Kingdom, <sup>5</sup>Clinical Academic Office, Newcastle University, Newcastle upon Tyne, United Kingdom

## Introduction

White matter hyperintensities (WMH, or leukoariaosis) are associated with increased risk of stroke, cognitive decline and dementia<sup>1</sup>. However, our knowledge of the pathophysiology of age-related white matter damage in the human brain remains incomplete, challenging our ability to develop treatment and prevention strategies. The imaging characteristics of deep white matter hyperintensities (DWMH) are consistent with ischemic damage and neuropathological studies show features of hypoxic and ischemic lesions. It is known that autonomic dysfunction is a feature of many of the clinical groups where white matter hyperintensities (WMH) are prevalent and significant correlations have been reported between measures of autonomic control and WMH burden<sup>2</sup>. Such data support the view that altered white matter perfusion may be causative in formation of DWMH, but we extend this hypothesis to stress *temporal variation in perfusion* as a possible significant factor, over and above long-term or global reduction in white matter blood flow.

## Hypothesis

We hypothesize that transient changes in cerebral perfusion (as for instance caused by taking an upright position) may, over a long period, lead to white matter lesions observed especially in the aging brain. We carried out a study using a quantitative fMRI technique in combination with the autonomic stressor: the Valsava manoeuvre (VM) to assess dynamic changes in white matter oxygenation and thus produce evidence in support of this hypothesis.

## Methods

**Subjects:** 16 elderly, community dwelling subjects (12 male, median age=80.5, interquartile range=77.5-85.5) were enrolled into the study and provided written informed consent. The study was approved by the local ethical committee.

**Scanning:** Functional MRI studies were performed using a 3T Achieva system (Philips Healthcare, Best, The Netherlands) using the body coil for transmission and 8-channel head coil as receiver with subjects performing 4 trials of the VM. The fMRI scan used a purpose written dual-echo gradient-echo EPI sequence<sup>3</sup> (TR=2000ms, TE1/TE2=13.82/39.27ms, 90° flip angle, 240×240mm<sup>2</sup> field of view, 112×112 matrix, 20 contiguous slices of 4 mm thickness).

**Autonomic Stressor:** The VM is performed by blowing into a closed outlet and maintaining an exhaled pressure of 40 mmHg for 16s. This causes phased, transient changes in arterial blood pressure, heart rate and cardiac output which must be compensated by the autonomic system and cerebral autoregulation<sup>4</sup>. Real-time feedback of pressure and cueing instructions to perform the VM concurrently with fMRI were viewed through the scanner presentation system.

**Analysis:** R<sub>2</sub><sup>\*</sup> images were calculated from the dual-echo data and analysed using GLM (FEAT FSL). We modelled responses to VM based on extracted global measures of the R<sub>2</sub><sup>\*</sup> time course. Mixed effects statistics were used ( $z > 2.3$ ,  $p < 0.05$ , cluster corrected).

## Results

Tissue oxygenation significantly decreased (increasing R<sub>2</sub><sup>\*</sup>) during the VM (Fig. 1A). GLM analysis revealed no significant signal changes in the grey matter (GM) while posterior white matter showed highly significant tissue deoxygenation (Figure 1B) in the watershed zone between middle (MCA) and posterior (PCA) cerebral arteries. These areas are associated with WMH formation<sup>5</sup>.

## Discussion

Watershed zones have been demonstrated to be particularly vulnerable to deoxygenation in line with the “stealing phenomenon” according to which GM is preferably defended against deficits in perfusion at an expense of the WM<sup>6</sup>. Thus our findings confirm particular vulnerability of the WM to transient deoxygenation during autonomic stress and lends support to the hypothesis that transient hypoxia is a mechanism for DWMH formation in the ageing brain.

## Acknowledgements

The research was funded by the National Institute for Health Research (NIHR) Newcastle Biomedical Research Centre based at Newcastle upon Tyne Hospitals NHS Foundation Trust

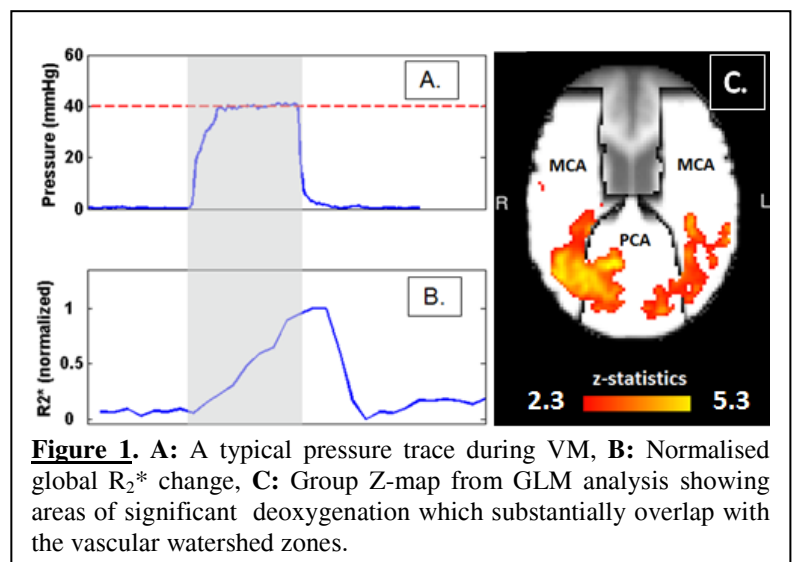
## References

- 1) DeBette, S. and H.S. Markus, *British Medical Journal*, 2010. 341: p. c3666.
- 2) Newton, J.L., et al., *Hepatology*, 2008. 48(2): p. 541-549.
- 3) He, J. et al., *Neuroimage Clinical*, 2: 168-173, (2013).

- 4) Dawson, S.L., et al., *J Appl Physiol*, 86, 675-680, (1999).

- 5) Enzinger, C., et al., *Journal of Neurology*, 2006. 253(8): p. 1064-1070.

- 6) Mandell, D.M. et al., *Stroke*: 39, 1993-1998, (2008)



**Figure 1.** A: A typical pressure trace during VM, B: Normalised global R<sub>2</sub><sup>\*</sup> change, C: Group Z-map from GLM analysis showing areas of significant deoxygenation which substantially overlap with the vascular watershed zones.