

Changes of leg- and hand-related corticospinal tract volumes during brain development

David O. Kamson^{1,2}, Csaba Juhasz^{1,2}, Harry T Chugani^{1,2}, and Jeong-Won Jeong^{1,2}

¹Pediatrics and Neurology, Wayne State University, Detroit, Michigan, United States, ²PET center, Children's Hospital of Michigan, Detroit, Michigan, United States

Target audience: developmental and rehabilitational neuroscientists. **Purpose:** This study aimed to assess the lateralization of the leg- and hand-related segments of the corticospinal tract (CST) during development. **Methods:** We performed diffusion tensor imaging (DTI) in 31 children (age: 1-14 years, mean age: 6±4 years), including 14 boys (5±2.5 years) and 17 girls (7±4.5 years). Seventeen children were healthy, typically developing (mean age 9±3 years) and 14 children had neurological disease without structural abnormalities (e.g., new onset epilepsy; mean age 3±1 years). MR scans were performed on a 3T GE-Signa scanner (GE Healthcare, Milwaukee, WI) equipped with an 8-channel head coil and ASSET. DWI was acquired with a multi-slice single shot diffusion weighted echo-planar-imaging (EPI) sequence at repetition time (TR) = 12,500 ms, echo time (TE) = 88.7 ms, field of view (FOV) = 240 mm, 128×128 acquisition matrix (nominal resolution = 1.89mm), contiguous 3mm thick axial slices using 55 isotropic gradient directions with $b=1000\text{s/mm}^2$, one $b=0$ acquisition, number of excitations (NEX)=1. Whole brain ICA+BSM (independent component analysis combined with a ball-stick model) tractography¹ was performed to reconstruct streamlines of white matter fibers, as described previously. To identify segments of streamlines, maximum *a posteriori* probability classifier² was applied, which can automatically classify individual streamlines into hand, leg, and face segments, based on their stereotactic atlases^{3,4} constructed from healthy children (**Figure 1**). For each segment, a streamline visitation map was created by the number of streamlines passing per voxel. Voxels having more than 5 visits were assigned to each motor pathway. Both absolute and relative streamline volumes (normalized to the hemispheric white matter volume) were calculated.

Mixed design analyses of variance (ANOVA) were performed examining the CST segmental volumes in relation to gender (inter-subject effect), left and right hemispheric location (intra-subject effect), and age included as a covariate. Separate analyses were done for the absolute and normalized leg- and hand-related CST volumes. CST volumes were also correlated with age using Pearson's correlation. **Results:** The absolute leg-related CST streamline volumes were higher in the left hemisphere ($p=0.001$) without a gender effect ($p=0.4$). No differences were found in the absolute hand-related CST stream-volumes ($p>0.4$). Normalized leg- and hand-related CST streamline volumes showed similar results. The normalized CST streamline volumes related to the leg steadily declined with age in the right hemisphere ($R=-.51$; $p=.004$) (**Figure 2**). This decline was also noted in both the subgroup of children with neurological conditions ($R=-0.6$; $p=0.02$) and in the healthy controls ($R=-0.5$; $p=0.04$). The leg-related CST streamline-volume remained relatively constant across ages in the left hemisphere ($r=-.07$; $p=.7$), as did the hand-related normalized CST stream volumes in either hemisphere ($R=.1$ and $-.1$ in the right and left hemispheres, respectively; $p>.5$). The absolute leg-related CST stream-volumes produced similar results to the normalized values in all correlations. **Discussion and Conclusion:** This study demonstrates developmental differences in the hand- and leg-related segments of the corticospinal tract in humans. The absolute and relative volume of the right CST, related to the leg (but not the hand) segment, shows a steady decrease between age 1 and 14 years, possibly due to gradual increase in the dominance of the left hemisphere. **References:** 1. Jeong et al., Magn Reson Med, 2013;70:441-53. 2. Jeong et al., Epilepsia 2013;54:1381-90. 3. Jeong et al., J Magn Reson Imaging, 2013;38:1152-61. 4. Jeong et al., Hum Brain Mapp, 2013 Oct 18.

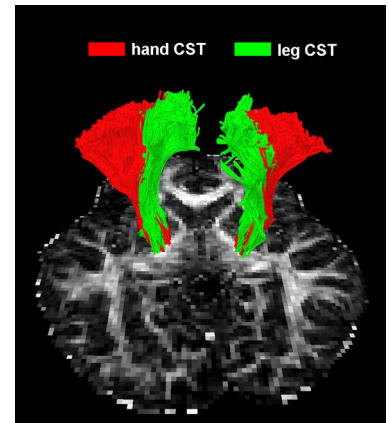


Fig 1. Hand (red) and leg (green) related fibers of the corticospinal tract in a DTI scan.

Normalized leg-related CST volumes correlated with age

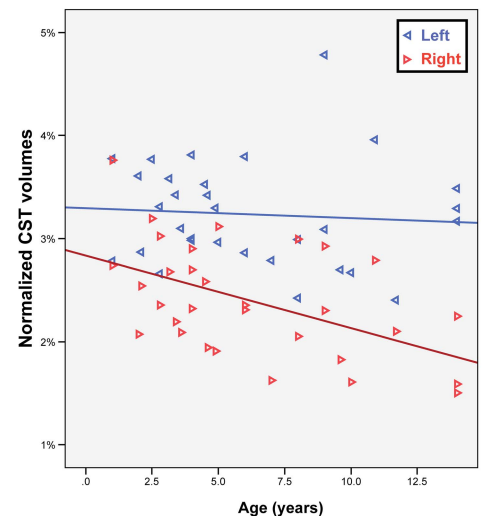


Fig 2. Normalized leg-related CST volumes (%) correlated with age (left hemispheric fibers are represented as blue arrows, right hemispheric fibers are represented as red arrows).