

## The Effect of Maternal Substance Abuse on Fetal Brain Growth

Devasuda Anblagan<sup>1,2</sup>, Kaiming Yin<sup>1</sup>, Rebecca M Reynolds<sup>3</sup>, Fiona Denison<sup>2</sup>, Mark E Bastin<sup>4</sup>, Colin Studholme<sup>5</sup>, James P Boardman<sup>2</sup>, Scott I Semple<sup>1,3</sup>, Neil Roberts<sup>1</sup>, and Jane E Norman<sup>2</sup>

<sup>1</sup>Clinical Research Imaging Centre, University of Edinburgh, Edinburgh, United Kingdom, <sup>2</sup>MRC Centre for Reproductive Health, University of Edinburgh, Edinburgh, United Kingdom, <sup>3</sup>Centre for Cardiovascular Sciences, University of Edinburgh, Edinburgh, United Kingdom, <sup>4</sup>Centre for Clinical Brain Sciences, University of Edinburgh, Edinburgh, United Kingdom, <sup>5</sup>Department of Pediatrics, University of Washington, Seattle, Washington, United States

**Target audience:** Researchers investigating fetal brain development.

**Purpose:** Retrospective motion correction is now possible for fetal brain MRI at the 2<sup>nd</sup> and 3<sup>rd</sup> trimester, making it possible to quantify early human brain development in utero. When combined with appropriate image analysis techniques, this allows reliable measurement of human fetal brain growth. In the present study, the Isotropic Cavalieri<sup>1</sup> method has been applied to analyse fetal brain 3D reconstructions in order to measure growth of brain in fetuses exposed to maternal substance abuse (methodone, diazepam and trazadone) compared to non-exposed fetuses.

**Methods:** **Scanning:** Following ethics committee approval, 46 healthy pregnant women were recruited and scanned on a 3 T Siemens MAGNETOM Verio at 24–27 weeks' (Visit 1; 26 women) and 36–38 weeks' (Visit 2; 38 women, 18 returned from first scan) gestation. Non-breath-hold, multi-slice, HASTE acquisitions were acquired three times in each of axial, sagittal and coronal scanning directions (25–50 slices, TE = 94 ms, 0.55 × 0.55 × 3 mm<sup>3</sup> voxels). The image series were motion corrected and reconstructed to form a single 3D high resolution brain image (1 × 1 × 1 mm<sup>3</sup>) using the Slice MRI Motion Estimation and Reconstruction (SLIMMER) tool<sup>2</sup>, with motion corrected data rated based on image quality (Figure 1). The resulting 3D datasets were used to estimate fetal brain intracranial, cerebellum and cerebral volumes, and arachnoid and pial surface areas (intracranial and cerebellum surface areas) using Isotropic Cavalieri<sup>1</sup> in Analyze 10.0 (MAYO Foundation, USA).

**Results and Discussion:** Details regarding the success of the motion correction algorithm are presented in Table 1. Reconstruction of fetal brain was not possible in 7 fetuses (27%) and poor in 6 fetuses (23%) from 2<sup>nd</sup> trimester and poor in 2 fetuses (5%) from 3<sup>rd</sup> trimester due to excessive fetal motion and bias field inhomogeneity. Movement was generally greater and more challenging to correct for during the 2<sup>nd</sup> trimester than the 3<sup>rd</sup>. So far, brain volume and surface area analyses are only conducted for data from 36–38 weeks; measurements were only possible for brain images rated A, B and C. The effect of exposure on fetal brain growth was assessed using a general linear univariate model based on one between-subject variable for all of the volume and surface area measurements. Two covariates were included in all analyses: gestational age at scan and birth weight. Fetuses exposed to maternal substance abuse showed significant reduction in intracranial volume ( $p = 0.03$ ) and cerebral volume ( $p < 0.03$ ), with this effect being greater on male fetuses' intracranial volumes. Although a similar trend can be seen for cerebellum volume and arachnoid and pial surface areas, these did not reach statistical significance. The cerebellum volume and pial surface area in female fetuses exposed to maternal substance abuse is significantly smaller compared to male exposed fetuses ( $p < 0.03$  and  $p < 0.02$ , respectively).

**Conclusion:** Fetal intracranial and cerebral volumes were reduced by maternal substance abuse.

**Future Work:** The analyses of motion corrected 3D fetal brain images will be conducted for data from 24–27 weeks. Analyses will be extended to include measurement of sub-regions of the fetal brain by adapting a variety of image analysis techniques, mainly semi-automatic segmentation methods based on edge detection, to study the growth in fetuses exposed to maternal substance abuse across gestation. This technique will be used to investigate the reliability of fetal brain measurements using the Isotropic Cavalieri method.

**References:** [1] Cruz-Orive LM, et al. (2010) J Microsc, 240 (2): 94-110, [2] Kim K, et al. (2010), IEEE Trans. Med. Imaging, 29 (1): 146-158.

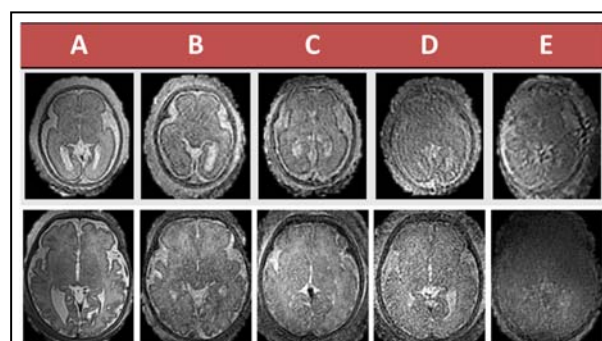


Figure 1: Image quality grading of motion corrected fetal brain images in the axial plane at 2<sup>nd</sup> (top row) and 3<sup>rd</sup> (bottom row) trimester: best (A), good (B), moderate (C), poor (D) and reconstruction failed (E).

Grading	Number of women recruited for 24–27 weeks (Visit 1)		Overall (%)	Number of women recruited at 36–38 weeks				Overall (%)
	Control	Substance		Returning Volunteers (Visit 2)		New Volunteers (Visit 1)		
				Control	Substance	Control	Substance	
A	6	4	38	5	3	9	1	47
B	0	1	4	5	1	8	2	42
C	1	1	8	2	0	0	0	5
D	3	3	23	2	0	0	0	5
E	6	1	27	0	0	0	0	0
<b>Total Recruit</b>	<b>16</b>	<b>10</b>	<b>26</b>	<b>14</b>	<b>4</b>	<b>17</b>	<b>3</b>	<b>38</b>
			<b>women</b>					<b>women</b>

Table 1: Details of the quality of motion corrected data at each gestation.

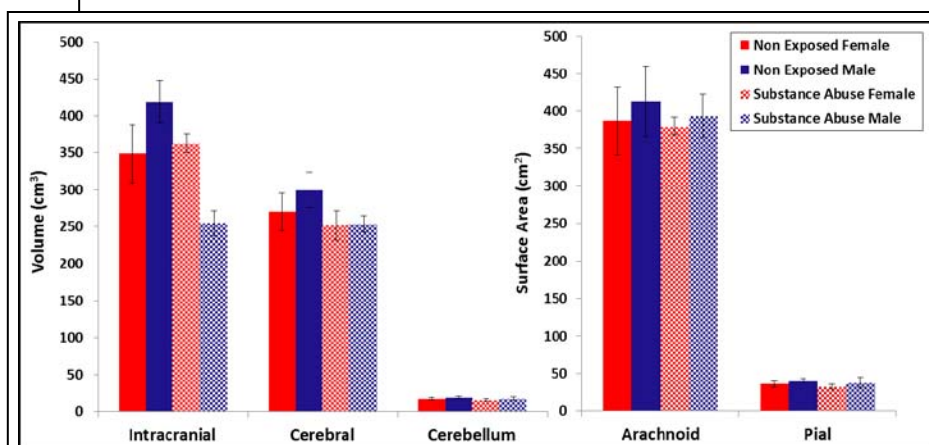


Figure 2: Effect of maternal substance abuse on fetal brain (intracranial, cerebral and cerebellum volumes, arachnoid and pial surface areas).