

# Acquisition of numerical, objective information on the Perfusion Territory Area using t-test based perfusion area measurement from multiple time points territorial arterial spin labeling (tASL)

Makoto Obara<sup>1</sup>, Morio Nagahata<sup>2</sup>, Tomoyuki Okuaki<sup>3</sup>, Nobuko Minagawa<sup>4</sup>, Masanobu Nakamura<sup>1</sup>, and Marc Van Cauteren<sup>3</sup>

<sup>1</sup>Philips Electronics Japan, Minato-ku, Tokyo, Japan, <sup>2</sup>Stroke Center, Yamagata City Hospital SAISEIKAN, Yamagata, Japan, <sup>3</sup>Philips Healthcare, Asia Pacific, Tokyo, Japan, <sup>4</sup>Department of Radiology, Yamagata City Hospital SAISEIKAN, Yamagata, Japan

**INTRODUCTION:** Territorial ASL (tASL) offers the opportunity, unique to MRI, to visualize vascular territories of main brain feeding arteries [1]. That information is compatible with digital subtraction angiography (DSA) findings and makes it possible to understand collateral circulation completely non-invasively [2]. Therefore, it potentially supplements or replaces DSA in the clinical assessment of patients with cerebrovascular disease or it can be used before and after vascular operation for checking and follow up. However, while visual assessment is used in clinical field to assess the information provided by tASL in conjunction with DSA images [2], simple and quantifiable assessment method is needed for wider use of tASL. We designed a new parameter Percentage Perfusion-Territory Area (%PT-A) to indicate the area of each arterial perfusion territory numerically and without intervention of the operator. The %PT-A's validity and clinical usefulness is discussed.

## METHODS:

**Subject and imaging parameters:** tASL data acquisition on a 3T clinical scanner (Philips Achieva R3.2) was performed in four healthy volunteers and three patients with cerebrovascular occlusive disease. All patients underwent surgical / Interventional reperfusion therapy and tASL imaging was conducted before and after the treatment. The tASL acquisition parameters were: FOV=240 mm, matrix=64x64, 7slices (6mm, 1.5mm gap), TR/TE=4000/16 ms, flip=40°, T11/ΔTI=550/250 ms (12 time points), SENSE=2.3, 30 label control pairs per territory. We adopted the dual vessel labeling approach, where two sets of labeling, labeling left carotid artery (LCA) and the vertebrasilar artery (VBA) in one and right carotid artery (RCA) and VBA in another provides the perfusion territory information [3]. Acquisition time was 4 min. 8sec. for each territory.

**t-test based perfusion mapping:** Perfusion signal in ASL is the difference between control and labeling scan signal. ASL generally acquires more than twenty data sets of control and label acquisition [1-3]. We used these data sets to conduct t-test for comparing labeling and control signal for each individual set as shown in Fig. 1. The t-test was conducted pixel by pixel. If the P value is less than 0.01, it was judged that there is perfusion signal. The pixels were then visualized in color for each territory, green for LCA, red for RCA and blue for VBA as shown in Fig. 1.

**Multiple time points sampling and accumulation map:** The logic of total amount of perfusion area measurement is explained in Fig. 2. Look-Locker readout strategy was used for ASL signal measurement [1-3]. To measure total perfusion area in each territory, all pixels which have a perfusion signal judged by the t-test at any of the time points were accumulated (accumulation map).

**Percentage Perfusion-Territory (%PT-A) calculation :** The number of the pixels in which there is perfusion signal was counted in each territory from accumulation map. Watersheds were also measured, explaining LCVB, LCA and VBA, RCVB, RCA and VBA, LCRC, LCA and RCA, and LRV, containing all territorial signals. Then ratio of each area regarding to total amount of area, territorial area / total area, was calculated (Percentage Perfusion-Territory Area: %PT-A).

**Evaluation :** In the examination with healthy volunteers, percentage stroke volume (%SV) of left and right internal carotid artery, and basilar artery were measured using phase contrast based quantitative flow measurement method and compared with %PT-A. In patients examination, %PT-A of post-treatment was compared with that of pre-treatment and assessed whether the changes of %PT-A are compatible with the changes of intracranial hemodynamics revealed by DSA.

## RESULTS:

**Healthy volunteer study :** Fig. 3 shows that %PT-A and %SV has strong correlation (R=0.94), suggesting the validity of %PT-A under the estimation that area of the perfusion has a linear relation with stroke volume in most of normal condition cases.

**Patients study :** %PT-A obtained in pre- and post-treatment periods indicated the changes of intracranial hemodynamics, which were visually observed on DSA in all of our 3 patients. Fig. 4 shows vertebral angiograms (VAG), tASL accumulation maps and %PT-A graphs in a patient with severe stenosis of the basilar artery (blue arrow). Balloon percutaneous transluminal angioplasty (PTA) was performed in this case. Those images were acquired in pre- and post-PTA periods. Bilateral posterior cerebral arteries (PCA) are clearly visualized on post-PTA VAG (blue circle area), while that area cannot be visualized on pre-PTA VAG. tASL accumulated map is in good agreement with the DSA finding, showing bilateral PCA territory as VBA territory which increased prominently after the treatment. That tASL finding is shown in a pie graph by using the numerical indicator of %PT-A.

**CONCLUSION:** Our results showed that %PT-A calculation using t-test based area-measurement and area-accumulation methodology could provide reliable and objective information. Clinical usefulness was also suggested for managing the cerebrovascular occlusive diseases. Further clinical trial is crucial to assess feasibility of this new approach.

**Reference:** 1. Xavier G et al, MRM 2005;53:15, 2. Soke MC et al, Stroke 2008;39:3248, 3. Zimine I, MRM 2006;56:1140

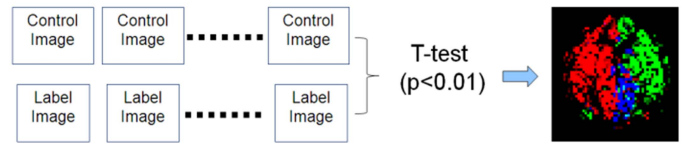


Fig. 1: T-test based ASL area measurement

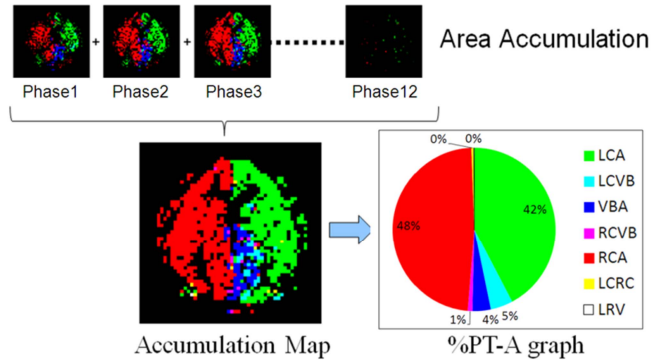


Fig. 2: Accumulation map and %PT-A graph

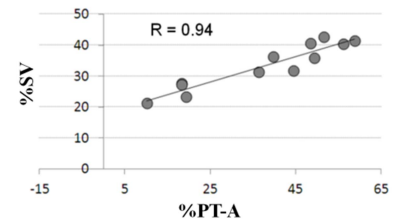


Fig. 3: %PT-A - %SV correlation

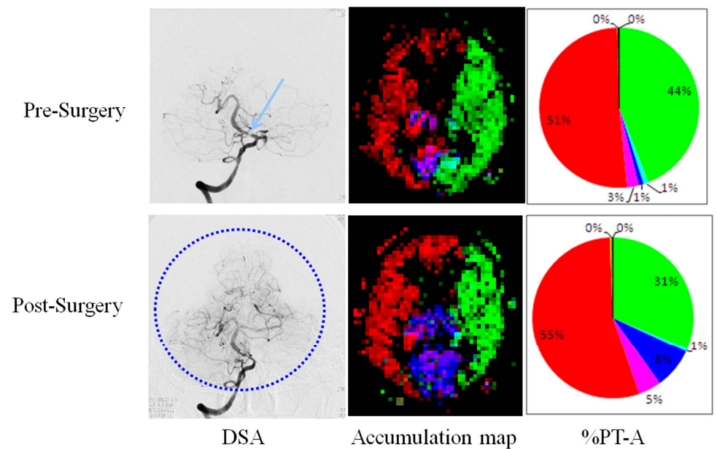


Fig. 4: MRA, Accumulated map and Area% graph