

DIFFUSION TENSOR IMAGING OF CERVICAL SPINAL CORD A 3T : NORMAL VALUES OF RADIAL, AXIAL, MEAN DIFFUSIVITY AND FRACTIONAL ANISOTROPY IN ANTERIOR HORN, DORSAL FUNICULUS AND PYRAMIDAL TRACT AT EACH CERVICAL LEVEL

Crombé Amandine^{1,2}, Menegon Patrice¹, Tourdias Thomas¹, and Dousset Vincent¹

¹Department of neuroradiology, Pellegrin Hospital, Bordeaux Segalen University, Bordeaux, France, ²ENS Lyon, Lyon, France

Target Audience : People interested in clinical applications for diffusion tensor imaging

Purpose : To build a robust cervical spine DTI sequence that could provide reproducible values with limited distortion in a clinically acceptable scan time.

To determine the normal values (mean, SD, maximum, minimum) of mean diffusivity (MD), axial diffusivity (AD), radial diffusivity (RD) and fractional anisotropy (FA) at each cervical level, in the entire cord section and in sub-regions.

Methods : From a commercially available SE-EPI DTI sequence, empirical optimization of the b-value, FOV, slice thickness, voxel size, number of excitations was conducted on a first group of ten healthy volunteers. Then, the optimal set of parameter, which provided minimum artefact and the smaller number of rejected slices, was used to collect data in a second set of twenty seven health subjects together with conventional sagittal T2SE and 3D MERGE.

The parametric maps from the DTI were motion corrected and merged with the anatomical sequences after exclusion of highly distorted sections. ROIs were manually positioned on Full spine section (FSC), posterior column (PC), anterior horn (AH) and cortico-spinal tract (CST) at every half cervical spinal level (C1, C1-C2...C6-C7, C7), on the right and on the left.

Results : The following set of parameters were found to provide the more consistent and less distorted images in 6mn50s scan time : 20 directions, $b = 750 \text{ mm}^2/\text{s}$, 3 excitations, matrix = 96×96 , FOV = $140 \times 140 \text{ mm}^2$, voxel size = $1.46 \times 1.46 \times 5 \text{ mm}^3$, TE = 103ms and TR = 6500ms. A shimming procedure was important while cardiac gating was not needed.

At each half cervical level, right and left DTI parameters did not show any significant difference.

However, at every level, white matter ROIs (PC and CST) showed significant differences with grey matter ROIs (AH), excepted at the "extreme" levels C1 and C7. For instance, at C4 level, FA in anterior horn was 0.59 ± 0.14 while FA in cortico spinal tract was 0.75 ± 0.04 .

FA had a tendency to decrease from C1 to C7, while MD and AD tended to increase, in CP, AH, CST and the entire section.

Discussion : This optimized sequence provides a referential of normal values of cervical spine diffusivity parameters depending on the cervical level and the anatomical structures. For further quantitative clinical study, axial and longitudinal location in cervical spine must be taken into account

Figure 1

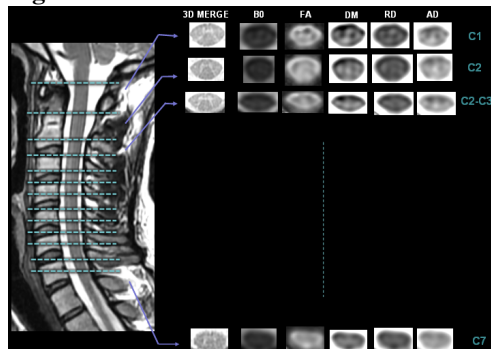


Figure 2

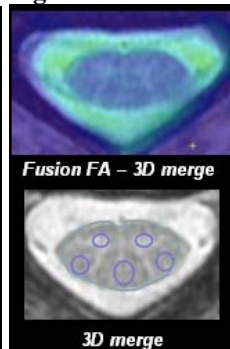


Figure 3

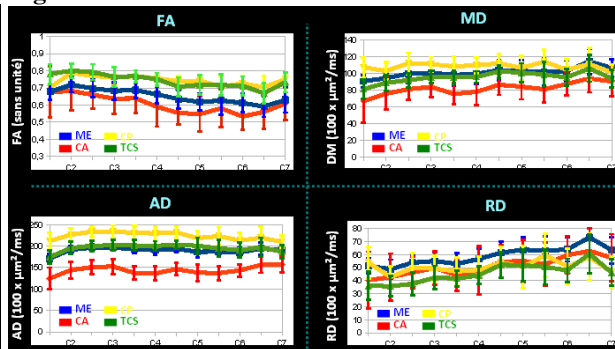


Figure 1: sequences and maps obtained in our protocol, **Figure 2 :** ROI propagation from anatomical 3D MERGE to DTI maps (FA, AD, RD, MD), **Figure 3 :** DTI parameters variations for anterior horn, posterior column, cortico spinal tract and full spine section

Acknowledgement : CHU de Bordeaux, GE Healthcare and OLEA Medical