

Correlation of DTI measures with neuropsychological scores in HIV-seropositive children

Bhaswati Roy¹, Rakesh K Gupta¹, Richa Trivedi², Alok Kumar Singh³, Ravindra Kumar Garg³, Yogita Rai⁴, Vimla Venkatesh⁵, Mukesh Tripathi⁶, and Chandra M Pandey⁷

¹Radiology & Imaging, Fortis Memorial Research Institute, Gurgaon, Haryana, India, ²NMR Research Centre, Institute of Nuclear Medicine and Allied Sciences, Delhi, Delhi, India, ³Neurology, King George's Medical University, Lucknow, Uttar Pradesh, India, ⁴Radiodiagnosis, Sanjay Gandhi Post Graduate Institute of Medical Sciences, Lucknow, Uttar Pradesh, India, ⁵Microbiology, King George's Medical University, Lucknow, Uttar Pradesh, India, ⁶Anaesthesiology, Sanjay Gandhi Post Graduate Institute of Medical Sciences, Lucknow, Uttar Pradesh, India, ⁷Biostatistics & Health Informatics, Sanjay Gandhi Post Graduate Institute of Medical Sciences, Lucknow, Uttar Pradesh, India

Introduction: Acquired immunodeficiency syndrome (AIDS) is a life-threatening disease caused by human immunodeficiency virus (HIV) and characterized by breakdown of the body's immune defenses. Pediatric HIV infection is a growing problem in most regions of the world. Vertical transmission is the main mode of infection among young children. The impact of the HIV virus on a child's neurodevelopment extends beyond the direct effect of the HIV on the central nervous system. Delayed neurodevelopment has been a well accepted complication of HIV disease (1). Neurological studies indicate that HIV CNS involvement can occur well before the first AIDS defining illness in as many as 18% of pediatric patients (2). HIV-related encephalopathy can present as static or progressive HIV encephalopathy, with microcephaly, delay or loss of developmental milestones, and pyramidal tract symptoms (3). The effect of HIV infection on mortality has been established, but the effect on the morbidity and neurodevelopment is not clear. Magnetic resonance imaging (MRI) an important tool for detection of CNS abnormalities often show nonspecific changes and only in the later stages of neurological deterioration. Diffusion tensor imaging (DTI) is a noninvasive imaging modality that measures the directional nature of water diffusion, which is given by cellular structures. This enables the technique to detect early alterations regarding the integrity of normal-appearing white matter in HIV patients. We assessed the integrity of white matter in HIV-seropositive pediatric patients through a voxelwise-based technique, using a white matter atlas previously determined. The purpose of this study is to compare the white matter integrity of HIV-seropositive children with HIV-seronegative children born to a HIV-seropositive mother of same socioeconomic status using DTI technique and relate them with cognition.

Materials and Method: We recruited 53 HIV-seropositive (age=10±2.3 years) and 8 HIV-seronegative controls of same socioeconomic status and quality of education. HIV infection was confirmed by enzyme-linked immunosorbent assay and western blot. Controls had no history of neurological illness. Based on the conventional MRI findings, HIV sero-positive patients (n=15) those showed hyperintensity on T2-weighted and FLAIR images were excluded from the study. All the statistical analysis was performed on 38 HIV infected pediatric patients and 8 controls. In both HIV infected patients and controls cognition was assessed using Indian adaptation of the Revised Amsterdamse Kinder Intelligence (RAKIT) Test.

MR Imaging: All MR imaging studies were performed on a 3T MR imaging scanner (Signa Hdx; GR Healthcare, Milwaukee, Wisconsin). An 8-channel head coil was used for brain MR imaging. T2-weighted axial images were acquired with TR=9200 ms, TE=72 ms, NEX=1, section thickness=3 mm, flip angle=90°, acquisition matrix=512×256, FOV=240 mm, reconstructed matrix=1024×1024. Parameters of FLAIR imaging were TR=9000 ms, TE=128 ms, TI=2400 ms, NEX=1, section thickness=3 mm, flip angle=90°, acquisition matrix=320×256, FOV=240mm, reconstructed matrix=512×512. DTI data were acquired by using dual spin-echo single-shot echo-planar sequences with 30 uniformly distributed directions with ramp sampling. The acquisition parameters were the following: TR=17 sec, TE=88.7 ms, number of sections=62, section thickness=3 mm, intersection gap=0, FOV=240×240 mm, image matrix=256×256, NEX=1, diffusion-weighting b factor=1000 s/mm².

Diffusion Tensor Image Processing: The Diffusion Toolbox software tool in FMRIB (<http://fsl.fmrib.ox.ac.uk/fsl/fslwiki>) was used for calculating the DTI indices. The DWIs were corrected for eddy current induced distortions and minor head movements by using affine registration to the reference B0 images. The Brain Extraction Tool was used for extracting the brain.

TBSS and Voxelwise Analysis: Voxelwise analysis of FA was performed by using TBSS, part of the FSL package. Individual skeletonized FA maps were aligned to the MNI152 template by using the Nonlinear Registration Tool in FMRIB. Each subject's aligned FA map was then projected onto this skeleton, and the voxelwise general linear model was applied by using permutation-based nonparametric testing, corrected for multiple comparisons. The correlation analyses were performed to study the relationship between neuropsychological scores and FA in the WM by using neuropsychological scores as regressors in the framework of a general linear model.

Results: TBSS analysis showed significantly reduced FA values in patients compared with controls in number of white matter regions, which included the frontal, parietal, and temporal lobes, corpus callosum (CC), corona radiata and posterior limb of internal capsule and its associated fibers (Fig1). Correlation maps showed a significant positive correlation between the memory function and FA values in CC (Fig2).

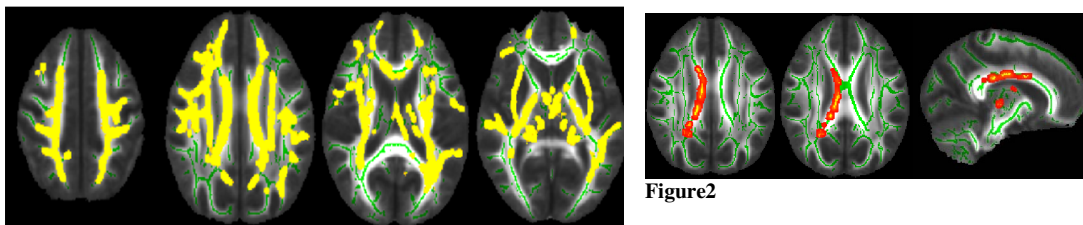


Figure2: Correlation between FA and Memory scores. Statistical maps shows voxels that correlate with memory scores

Figure1: Statistical maps showing voxels which exhibit differences in DTI parameters in HIV negative children and HIV positive children both from HIV positive mother. FA is significantly decreased in HIV positive children group in comparison to HIV negative children. Differences are widespread and evident in various WM regions. All WM tracts are overlaid on MNI152 1-mm standard image. (TBSS analysis, two-sample, $p < 0.05$, t_{corrected}).

Discussion:

Our data showed significantly reduced FA in CC, corona radiata, posterior limb of internal capsule and white matter of frontal, parietal, and temporal lobes in patients compared to controls. The memory scores positively correlated with FA in CC. The predominant histopathology features in HIV infection are myelin loss, along with pericapillary multinucleated giant cells, reactive astrocytosis, and microglial activation with microglial nodules (4). Changes in FA in our study could be associated with above mentioned pathological process. Our findings suggest that the microstructure changes in WM are quite widespread in the brain, even when patients showed no abnormalities on conventional imaging. DTMRI could play a role as an early marker of HIV related brain changes.

References: (1) Rie et al. Pediatrics 2008;122:e123-e128; (2) Gabuzda and Hirsch. Ann Intern Med. 1987;107:383-391; (3) Belman et al. Am J Dis Child. 1988;142:29-35; (4) Smith et al. RadioGraphics 2008;28:2033-2058.