

Prostate MRI : comparison of generalized autocalibrating partial parallel acquisition (GRAPPA) -accelerated readout-segmented echo-planar imaging (EPI) and single-shot EPI in clinical application of diffusion-weighted imaging at 3 T

Liang Li¹, Liang Wang¹, Hui Liu², Ming Deng¹, Zhao-Yan Feng¹, and Ji-Hong Liu³

¹Department of Radiology, Tongji Hospital, Tongji Medical College, Huazhong University of Science and Technology, wuhan, hubei, China, ²Siemens Healthcare, Shanghai, China, ³Department of Urology, Tongji Hospital, Tongji Medical College, Huazhong University of Science and Technology, wuhan, hubei, China

Purpose: Readout-segmented echo-planar imaging(EPI) has been suggested as an alternative to single-shot EPI for diffusion-weighted imaging(DWI) with reduced distortion[1,2]. However, clinical comparisons of readout-segmented EPI and standard EPI DWI are limited by unmatched imaging parameters and reconstruction procedures. The purpose of this study was to compare the clinical utility of generalized autocalibrating partial parallel acquisition(GRAPPA)-accelerated readout-segmented EPI(rs-EPI) DWI with single-shot EPI (ss-EPI) DWI for visualization of the prostate at 3.0 T MRI.

Material and Methods: The local Institutional Review Board (IRB) approved this retrospective study and waived the requirement of informed consent. Between April 2013 and October 2013, 36 consecutive patients (mean age, 62 years; range 45-87 years) were enrolled in the study. The clinical indications for prostate MRI included characterization or follow-up of prostate lesions and oncologic follow-up. All MR examinations were performed on a 3.0 T MR system (MAGNETOM Skyra, Siemens Medical System, Erlangen, Germany). Images were obtained using GRAPPA-accelerated rs-EPI and ss-EPI with an identical scanning time, acceleration factor, target resolution, and image postprocessing procedure. DWI was performed with b-values of 0 and 800 s/mm². The two datasets were independently reviewed by two blinded urogenital radiologists. Imaging studies were evaluated for resolution, signal-to-noise ratio (SNR), contrast-to-noise ratio(CNR), distortion, lesion conspicuity, and diagnostic confidence using a 7-point Likert scale: 1, nondiagnostic; 2, poor; 3, acceptable; 4, standard; 5, above average; 6, good; and 7, outstanding. Observer agreement was assessed using a linearly weighted kappa statistic. Tests for differences in ratings between ss-EPI and rs-EPI were performed using a two-tailed Wilcoxon signed-rank test, p<0.05 considered significant.

Results and Discussion: The readers were in good agreement in their scores ($\kappa = 0.68$; 95%CI, 0.56-0.79). The mean scores for ss-EPI and GRAPPA-accelerated rs-EPI, respectively, were as follows: resolution, 3.4/5.8; distortion level, 2.9/5.9; SNR, 3.8/4.2; CNR, 3.2/3.8; lesion conspicuity, 4.0/5.6; and diagnostic confidence, 3.2/5.1. Overall, GRAPPA-accelerated rs-EPI was superior to ss-EPI in resolution, distortion reduction, lesion conspicuity, and diagnostic confidence (P =0.006), whereas EPI scored better in SNR and contrast. Readout-segmented EPI was considered the better sequence overall in 98.7% of the cases. Moreover, the higher spatial resolution as well as reduced blurring and distortions on rs-EPI scans helped to better reveal important anatomic details such as central zone, peripheral zone, surgical capsule, benign hyperplastic nodule, extracapsular extension and lymph node metastasis of prostate cancer.

Conclusion: GRAPPA-accelerated readout-segmented echo-planar imaging (rs-EPI) enables robust prostate imaging with an short acquisition time, providing improved resolution and reduced distortion in evaluating the prostate.

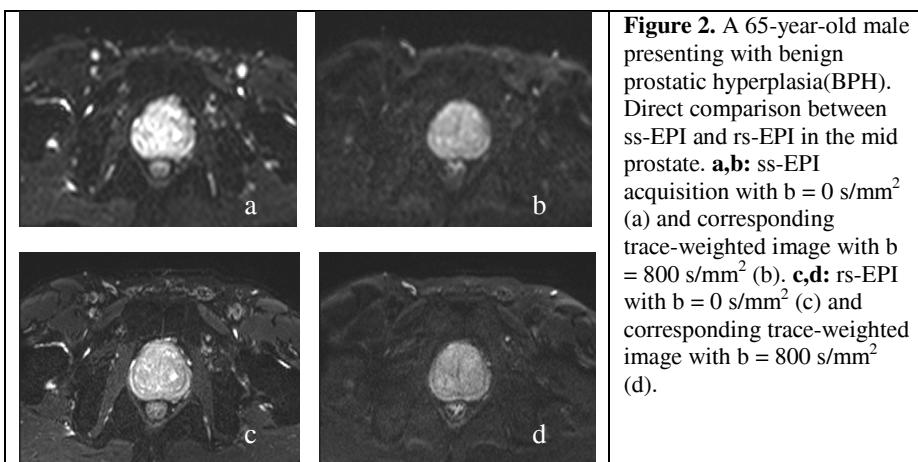


Figure 2. A 65-year-old male presenting with benign prostatic hyperplasia(BPH). Direct comparison between ss-EPI and rs-EPI in the mid prostate. **a,b:** ss-EPI acquisition with b = 0 s/mm² (a) and corresponding trace-weighted image with b = 800 s/mm² (b). **c,d:** rs-EPI with b = 0 s/mm² (c) and corresponding trace-weighted image with b = 800 s/mm² (d).

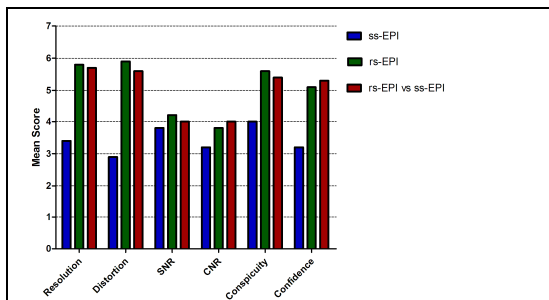


Figure 1. Histogram of image quality scores assigned in 36 patients with DW MR imaging with ss-EPI and with rs-EPI. Image quality was rated with a 7-point Likert scale.

References:

- [1] Eiber M, Beer AJ, Holzapfel K, et al. Invest Radiol. 2010;45:15-23.
- [2] Porter DA, Heidemann RM. Magn Reson Med. 2009;62:468-475.