

Tissue-specific Variable Flip Angle of 3D Turbo-Spin Echo on 3.0T system: Optimized with Individual T1 and T2 value for Prostate.

Katsusuke Kyotani¹, Yoshiko Ueno², Satoru Takahashi², Yu Ueda¹, Tomoyuki Okuaki³, Nobukazu Aoyama¹, Kazuhiro Kitajima², Hideaki Kawamitsu¹, and Kazuro Sugimura²

¹Division of Radiology, Kobe University Hospital, Kobe, Hyogo, Japan, ²Department of Radiology, Kobe University Graduate School of Medicine, Kobe, Hyogo, Japan, ³Philips healthcare Asia pacific, Minato-ku, Tokyo, Japan

Introduction:

MRI is now widely used for prostate cancer diagnosis. Because visualization of zonal anatomy and the prostate capsule is vital for lesion detection and staging, high spatial and contrast resolution is desirable for T2WI that plays a central role in the morphological prostate MRI. Although 3D turbo-spin echo sequence (standard 3D-TSE) was expected to improve diagnostic accuracy with providing continuous high resolution thin-slice images, it often suffers from blurring and degenerated contrast resolution due to long echo train length with fix flip angle sweep¹. Recently, 3D-TSE with variable refocusing flip angle for specific T1 and T2 values (tissue-specific VRFA 3D-TSE) have been applied to decrease blurring and obtain better contrast for 3D-TSE imaging^{2,3}. Our aim was to evaluate the usefulness of tissue-specific VRFA 3D-TSE optimized with measured T1 and T2 values of prostate gland comparing to standard 3D-TSE for T2W imaging.

Material and Method:

Twelve volunteers (mean age 58±10y) underwent prostate MRI at 3.0T systems using a 2channel transmit system and a 7-channel cardiac coil. Scans included tissue-specific VRFA and standard 3D T2W-TSE imaging sequence (TR 1500 ms; TE 190 ms; FOV 22×22 cm; matrix 320×320; slice thickness 1.1 mm; SPIR; parallel imaging factor 2.0). For tissue-specific VRFA 3D T2W-TSE, flip angles of refocusing pulses are automatically optimized for each subject by applying T1 and T2 value of a prostate peripheral zone (PZ) measured with separate sequence. In standard 3D T2W-TSE, on the other hand, the first echo was collected with a refocusing pulse of 160 degrees, followed by rapid decrease of flip angles down to 80 degree. Contrast ratio (CR) was calculated from ROI measurements of PZ / PZ cancer and PZ / transition zone (TZ) in each patient. Spatial resolution ratio (SRR) was also calculated by using half maximum full-width (FWHM) as edge response function. Each CR and SRR was compared by two-side Student's t test.

Result:

Representative case is shown in Figure 1. CR between PZ and PZ cancer of the tissue-specific VRFA 3D T2W-TSE was significantly higher than that of standard 3D T2W-TSE 0.099 ± 0.095 ($P < 0.05$) (figure 2). CR between PZ and TZ of the tissue-specific VRFA 3D T2W-TSE was significantly higher than that of standard 3D T2W-TSE 0.074 ± 0.056 ($P < 0.05$) (figure 3). SRR of tissue-specific VRFA 3D-TSE was improved 0.189 ± 0.15 compared to standard 3D-TSE ($P < 0.05$) (figure 4, 5).

Conclusion:

Tissue-specific VRFA 3D-TSE has a potential to improve contrast ratio and spatial resolution ratio of prostate MR imaging at 3.0T system, when compared with standard 3D-TSE.

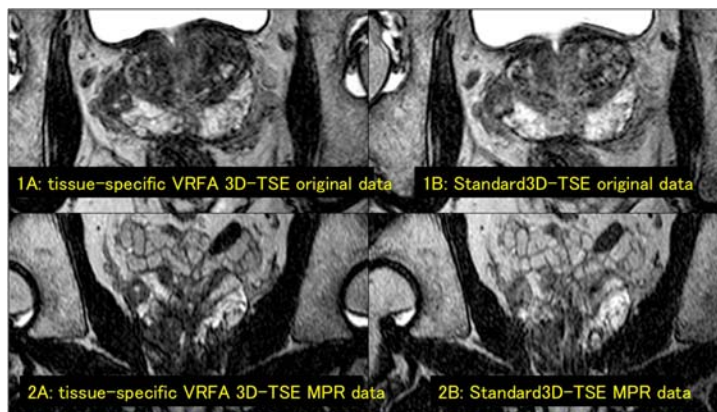


Figure 1. Axial and coronal-MPR T2W-images obtained tissue-specific VRFA and standard 3D-TSE.

1A: tissue specific VRFA 3D-TSE original axial data
1B: standard 3D-TSE original axial data
2A: tissue specific VRFA 3D-TSE MPR coronal data
2B: standard 3D-TSE MPR coronal data

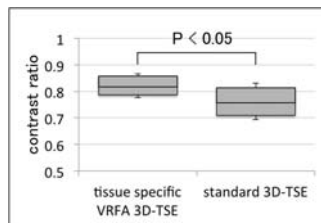


Figure 2. Comparison of tissue specific VRFA 3D-TSE with standard 3D-TSE that contrast ratio between PZ and PZ cancer.

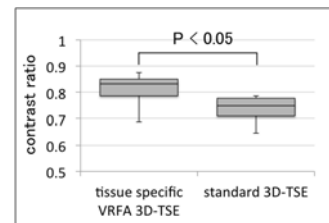


Figure 3. Comparison of tissue specific VRFA 3D-TSE with standard 3D-TSE that contrast ratio between PZ and TZ.

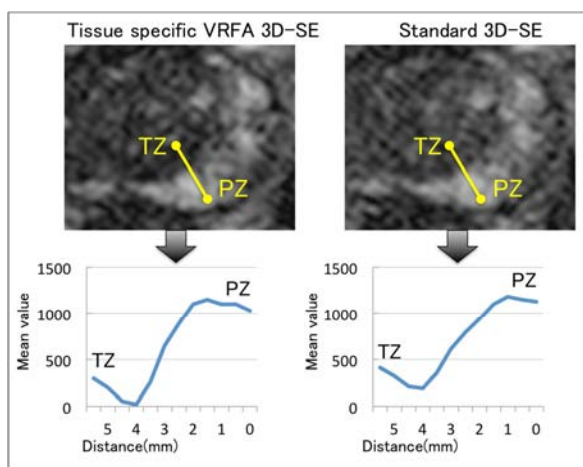


Figure 4. Comparison of tissue specific VRFA 3D-TSE with standard 3D-TSE of edge response function curve between TZ and PZ.

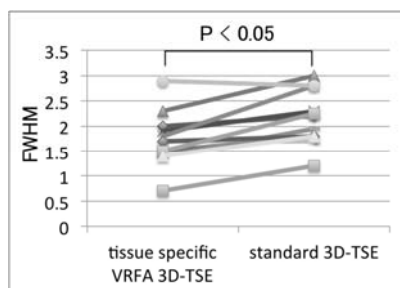


Figure 5. The spatial resolution improvement rate of tissue-specific VRFA 3D-TSE on the basis of standard 3D-TSE.

Reference:

- [1] David C. Alsop. Magn Reson Med 1997 Feb; 37(2): 176-84.
- [2] Anthony Vu, et al. Magn Reson Med 2006 May; 55(5): 1030-7.
- [3] Reed F. Busse, Anja C.S. Brau, Anthony Vu, et al. Magn Reson Med 2008 Sep; 60(3): 640-9