

INCREASED GRAY MATTER DENSITY IN PARALLEL WITH INCREASED CONNECTIVITY IN PARKINSON DISEASE

Mihaela Onu¹, Liviu Badea², and Adina Roceanu³

¹Medical Imaging, Clinical Hospital "Prof. dr. Th. Burghiele", Bucharest, Romania, ²National Institute for Research in Informatics, Bucharest, Romania, ³University Emergency Hospital Bucharest, Bucharest, Romania, Romania

TARGET AUDIENCE: Clinicians with interest in Neurodegenerative (Parkinson) diseases studies. Medical physicists interested in morphological-functional correlations in neurodegenerative diseases.

PURPOSE: We hypothesized that, in Parkinson disease (PD), gray matter density and functional cerebral connectivity might develop compensatory behaviors in response to the damaged motor control loops (the basal ganglia-thalamocortical circuit (BTC) and cerebello-thalamocortical circuit (CTC)), especially at the basal ganglia/thalamic level.

METHODS: Fourteen PD patients and 9 age and sex matched healthy volunteers were investigated with a 1.5 T MRI system. MPRAGE sequence for gray matter structural data (further analysed by FSL-VBM) and Echo Planar sequence for resting state fmRI (analysed with FSL-Melodic and FSL-Dual regression to run a group-comparison ICA), have been used.

RESULTS: Group comparison Voxel-based-morphometry (VBM) revealed increased gray matter density in right thalamus (figure 1) ($p < 0.02$, uncorrected for multiple comparisons). Resting state fmRI Dual regression performed on Basal ganglia network obtained by ICA, showed marked increased connectivity in right thalamus area (figure 2) and in left putamen, globus pallidus and a small area in thalamus (figure 2, right) ($p < 0.02$, corrected for multiple comparisons).

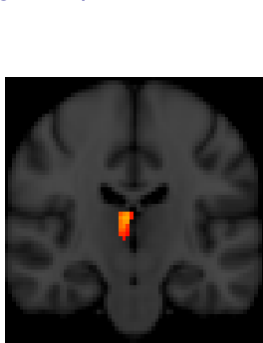


Figure 1: VBM results: increased gray matter density (red-yellow) was found in the right thalamic area (standard space).

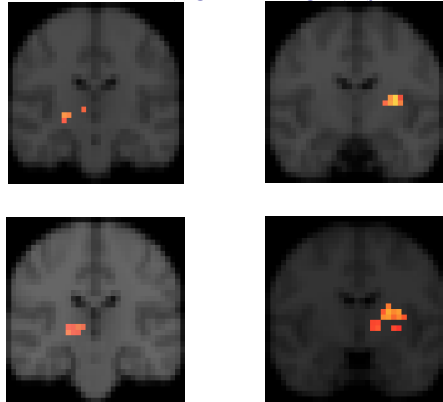


Figure 2: Dual regression performed for Basal ganglia network (ICA) show increased connectivity (red-yellow) in areas involving right thalamus (left: top, Z=27, bottom, Z=26) and left putamen/pallidus/globus pallidus (right: top Z=29, bottom, Z=30), (standard space).

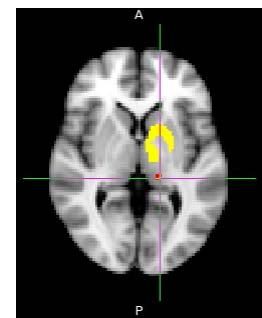


Figure 3: FCA analysis performed for specific regions (from Shirer parcellation) found significant increased connectivity between left thalamus subregion (red structure) and basal ganglia (yellow structure).

We also performed a second analysis of functional connectivity (FCA) between specific regions using the resting state parcellation of Shirer et al. (2012). We observed a significant increase in functional connectivity between specific region from the left thalamus and basal ganglia, as shown in figure 3 ($p < 7.7 \times 10^{-4}$). We also observed, using FCA, an increased functional connectivity between the same left thalamic region and a corresponding right thalamic region ($p < 4 \times 10^{-4}$), which is presumably indirect (not shown here).

DISCUSSION: Conventional literature has consistently demonstrated how the thalamus receives inhibitory inputs from the GPi (internal part of globus pallidus) and the SN (substantia nigra), and then projects excitatory output to the cortex. In line with the BTC loop, the inhibitory signal from the GPi and SN is weaker in PD patients as compared to healthy controls. Over the long run, therefore, thalamus enlargement may occur due to a decreased inhibitory signal. Our study brings new proofs for thalamic enlargement. The increases in gray matter density might reveal compensatory effects or self-reorganization. We hypothesized that the structural changes were associated with functional changes. Previous studies using (F^{18} dopa) PET showed a regional hypermetabolism in the thalamus in PD patients. We used resting state fmRI to investigate potential hyperconnectivity at the basal ganglia/thalamic level: no decrease connectivity were found for PD patients compared to healthy volunteers, on the contrary, an increased connectivity was detected in the right thalamic area and left putamen and globus pallidus. An additional analysis for connectivity between specific regions, FCA, proved increased connectivity between thalamus and basal ganglia. The thalamic enlargement found in parallel with an increased connectivity at basal ganglia/thalamic level may reflect a compensatory effect in response to the damaged motor control loops, the BTC, or to the CTC loops.

CONCLUSION: Thalamic increased volume might be due to enhanced thalamo-motorcortical interaction which is known to be present in PD. The increased connectivity at thalamic and basal ganglia level in PD patients compared to healthy volunteers seems to confirm this hypothesis.