

High resolution fMRI reveals laminar specific resting-state functional connectivity in primary somatosensory cortex in non-human primates

Shantanu Majumdar^{1,2}, Feng Wang^{1,2}, Li Min Chen^{1,2}, and John C Gore^{1,2}

¹Vanderbilt University Institute of Imaging Science, Vanderbilt University, Nashville, TN, United States, ²Department of Radiology and Radiological Sciences, Vanderbilt University, Nashville, TN, United States

Introduction

fMRI detects regional activity changes produced by specific stimuli, but few studies have resolved the contributions of different cortical layers to measured BOLD signals [1, 2]. Moreover, resting-state correlations are used to infer functional connectivity, but little is known about how such correlations vary spatially with cortical depth. Here we report studies using sub-millimeter resolution resting-state functional MRI of primary somatosensory (S1) cortex in anesthetized squirrel monkeys where we examined laminar specific functional connectivity between sub-regions (area 3a, area 3b and area 1). These studies allow improved understanding of the nature of inter-layer connectivity and how these change with neurological disorders or injury [3].

Method

Three squirrel monkeys are scanned using a 9.4T MRI/MRS spectrometer (Agilent Technologies, Palo Alto, CA, USA) while under isoflurane anesthesia (0.5-0.8%) with a 3 cm diameter transmit-receive surface coil positioned over the central sulcus. Throughout the procedure, the animal's vital signs are monitored. A set of coronal, axial and oblique anatomical images are used to guide the placements of transcortical imaging planes through the digit regions within S1 cortex (underlay image in Fig. 1(b)). We collect 8 slices of T₂*-weighted transcortical structural images (TR/TE=200/16 ms, 1 mm slice thickness) and functional MRI images using a gradient-echo EPI sequence with the following parameters: TR=3000 ms, TE = 16 ms, in-plane resolution = 0.273 x 0.273 mm², 1 mm slice thickness, 4 shots with centric k-space order, triple reference scan for phase correction, 300 volumes for each run. Multiple runs were collected within each imaging session. A vibrotactile (digit 2, D2)

stimulus driven fMRI experiment (with alternating 30 s stimulus and rest blocks, 7 epochs) is performed to identify the digit region for seed based resting-state fMRI analysis (Fig. 1(b)).

The resting-state functional connectivity analysis was performed using AFNI and Matlab modules. The EPI data were pre-processed using the following steps: slice timing correction, S1 region masking, volume co-registration, scanner drift correction, regression of nuisance parameters (motion, muscle and white matter signals), band-pass filtering to suppress respiratory and cardiac signals. A seed region in area 3b of S1 cortex was selected based on the digit activation map to vibrotactile stimulation. Then resting-state time courses in seed voxels from 3 different depths in the 3b region were used for an ROI based correlation analysis to the other regions of the S1 cortex. The correlation maps were thresholded at $p < 0.001$ (uncorrected).

Results and Discussion

Fig. 1(b) shows the D2 activation pattern in areas 3a, 3b and 1 in a single subject that was used as a guide to select the seeds in area 3b for the resting-state analysis. The cortical thickness is around 2.2 mm at the area 3b (Fig. 1(c)). The seed voxel in the superficial layer in 3b (at around 25% depth (Fig. 1(c)) from pial surface) is strongly correlated with the superficial layer of areas 1 and 3a. Interestingly, at the location corresponding to the palm region between areas 1 and 3b digit regions, there is a cluster of highly correlated voxels at the lower layers of the cortex. With the seed at the middle layer in area 3b (at around 50% depth in Fig. 1(d)), strongly correlated voxels also appeared at the middle layer of areas 1 and 3a, but with a decreased strength of correlation. Further when the seed was placed at the lower layer of area 3b (at around 75% depth in Fig. 1(e)), a small cluster of correlated voxels

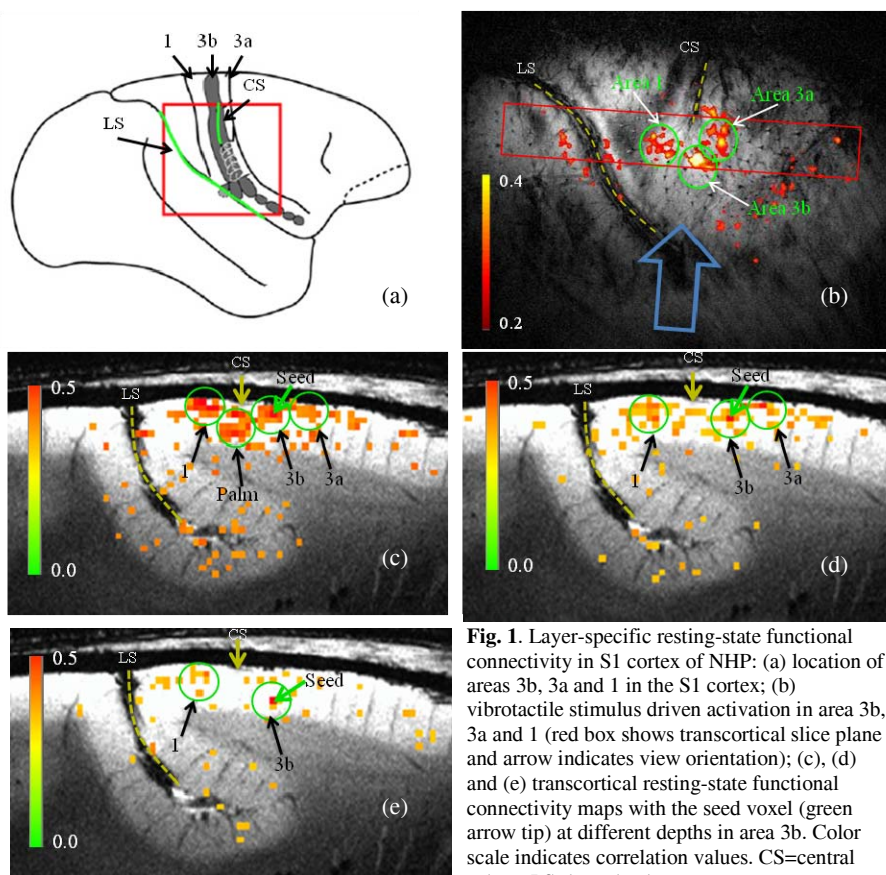


Fig. 1. Layer-specific resting-state functional connectivity in S1 cortex of NHP: (a) location of areas 3b, 3a and 1 in the S1 cortex; (b) vibrotactile stimulus driven activation in area 3b, 3a and 1 (red box shows transcortical slice plane and arrow indicates view orientation); (c), (d) and (e) transcortical resting-state functional connectivity maps with the seed voxel (green arrow tip) at different depths in area 3b. Color scale indicates correlation values. CS=central sulcus, LS=lateral sulcus.

at lower layer of area 1 is present. While previous studies on S1 cortex have shown local and regional resting-state functional connectivity maps [4], this work advances our understanding of laminar functional connectivity networks within fine-scale digit regions. Further studies are needed to examine the consistency of the connectivity pattern.

This study showed the feasibility of performing high resolution laminar fMRI on non-human primates. One of the difficulties in the analysis of fMRI data is the removal of confounding factors due to physiological noise such as respiratory and cardiac effects. While we have regressed out effects arising from the muscle and white matter, effects of pial and transcortical veins in the vicinity of the central sulcus could introduce spurious correlation in the functional connectivity analysis. One way to identify and eliminate such effects will be to use a multi-echo EPI sequence and perform R₂* mapping [5].

References

- [1] Shih, Y. Y., et. al., *Neuroimage*. 2013; 73:113-20, [2] Herman, P., et. al., *Proc Natl Acad Sci U S A*. 2013; 110(37):15115-20, [3] Chen, L. M., et. al., *J Neurosci*. 2012; 32(42):14649-63. [4] Wang, Z., et. al., *Neuron*. 2013; 78(6):1116-26, [5] Kundu, P., et. al., *Neuroimage*. 2012;60(3):1759-70.