

The Effect of Hypoxia on Resting-State Functional Connectivity in the Human Brain

Ravjit Singh Sagoo¹, Habib Ganjgahi², Eddie Ng'andwe¹, Mahmud Saedon³, Sarah Wayte⁴, Alex Wright^{5,6}, Arthur Bradwell^{5,6}, Charles Hutchinson^{1,7}, Christopher Imray^{3,6}, and Thomas Nichols²

¹Department of Imaging, University Hospitals Coventry and Warwickshire NHS Trust, Coventry, United Kingdom, ²Department of Statistics, University of Warwick, Coventry, United Kingdom, ³Department of Surgery, University Hospitals Coventry and Warwickshire NHS Trust, Coventry, United Kingdom, ⁴Department of Medical Physics, University Hospitals Coventry and Warwickshire NHS Trust, Coventry, United Kingdom, ⁵University of Birmingham, Birmingham, United Kingdom, ⁶Birmingham Medical Research Expeditionary Society, Birmingham, United Kingdom, ⁷University of Warwick, Coventry, United Kingdom

Target Audience

Radiologists, neurosurgeons, neurologists, and physicians with an interest in basic physiology.

Purpose

Rapid ascent to high altitude results in reduced arterial oxygen levels that will frequently lead to symptoms. It is believed that one of the processes responsible for maintaining cerebral oxygen delivery in these subjects is an increase in cerebral flow. Despite maintaining oxygen delivery, many climbers are prone to developing acute mountain sickness (AMS) or high altitude cerebral oedema (HACE), the mechanisms of which remain poorly understood. Symptoms can include headache and gastrointestinal symptoms, but also cognitive and behavioural changes. As there are changes in cerebral blood flow in response to hypoxia, we postulate that this may result in changes in the brain's resting-state functional connectivity and, therefore, could be studied using the blood-oxygen level dependent (BOLD) contrast utilized by resting-state functional MRI (rs-fMRI).

Methods

Subjects (n=12) underwent 3-T MRI scanning (GE HDxt, Milwaukee USA) at baseline (FiO₂=21%) and at 2, 4, 6, 11 and 22 hours of continuous normobaric hypoxia (FiO₂=12%, approximately equivalent to an altitude of 4,400m). T1-weighted (structural) followed by BOLD fMRI sequences were acquired at rest. Imaging data were analyzed in FSL version 5.05 using standard preprocessing, including motion correction smoothing, high-pass filtering, and affine registration. Dual regression was used to create per-subject, per-time point volumes that could be analyzed for longitudinal effects, using the 10 ICA-generated networks as described by Smith et al¹. Baseline volume was subtracted from each hypoxic time point, producing 5 volumes per subject. An F-test was computed to test for any non-zero hypoxic changes from baseline. Inference was performed with threshold-free cluster enhancement (TFCE). Family-wise-error corrected whole-brain TFCE inferences were obtained using a permutation test with 5000 permutations with further Bonferroni correction for considering 10 components. The Lake Louise questionnaire was used to assess for AMS.

Results

10 out of 12 subjects completed the 22-hour study while 2 subjects dropped out due to symptoms after 11 hours. 10 subjects, including the 2 early retirees, developed AMS at differing time points. Significantly decreased connectivity due to hypoxia ($p < 0.05$) has been found in the visual network (map "1₂₀" in Smith et al¹), in a small area within the medial occipital pole (figure 1). The explicitly visual behavioral domains correspond most strongly to these maps, and paradigms cognition–language–orthography and cognition–space correspond to the occipital pole and lateral visual maps, respectively. Figure 2 shows the mean of hypoxic change to baseline in different time points in the entire significant cluster, revealing a sustained decrease in functional connectivity in this region throughout the hypoxic period.

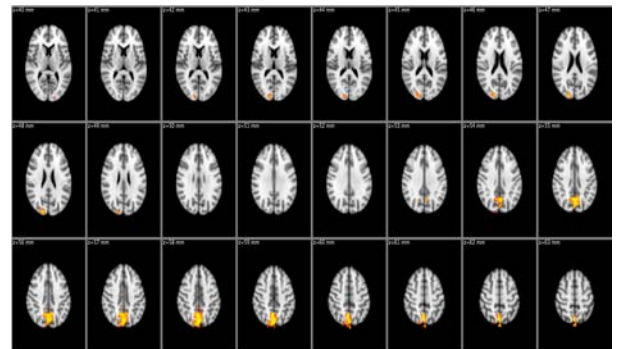


Fig 1: Significant clusters displaying decreased connectivity

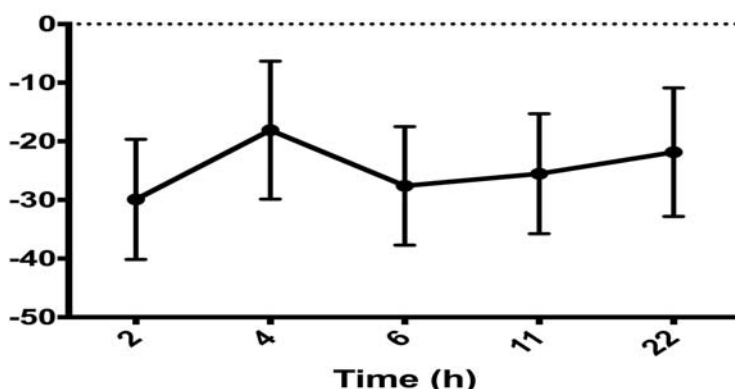


Fig 2: Level of hypoxic change (with 95% CI) in the significant cluster compared with baseline

Conclusion

Although this study has shown a small area of significant decline in functional connectivity in response to hypoxia within the 'visual maps', there does not appear to have been a global change in connectivity on rs-fMRI to fully account for the cognitive and behavioural changes associated with AMS. These results may suggest that alternative pathophysiological processes contribute to these symptoms.

References

1. Smith, S. M., Fox, P. T., Miller, K. L., et al. Correspondence of the brain's functional architecture during activation and rest. *Proceedings of the National Academy of Sciences of the United States of America*. 2009;106(31):13040–5