

The effect of left hemispherotomy surgery in patient with Rasmussen's syndrome using fMRI a case study

Kapil Chaudhary¹, S SENTHIL KUMARAN², Poodipedi Sarat Chandra³, and Manjari Tripathi¹

¹Neurology, All India Institute of Medical Science, New Delhi, Delhi, India, ²Department of NMR, ALL INDIA INSTITUTE OF MEDICAL SCIENCES, New Delhi, Delhi, India, ³Neurosurgery, All India Institute of Medical Science, New Delhi, Delhi, India

Purpose and Background: Intractable seizures may need to be treated with surgery if the seizure control in the patient is not achieved with medications. Although surgical resection is successful in curing up to 70% of patients, a significant risk of post-operative cognitive decline continues to limit its application (2). Functional MRI may play a role in observing the role of temporal lobe for any other cognitive functions.

Method: After obtaining the institute ethics approval a 10-year-old right-handed girl was recruited in study. We used fMRI to study the language and memory function in a during pre & post surgery sessions. FMRI was performed using single-shot echo planar imaging (EPI) sequence on 1.5T MR scanner (Avanto, Siemens, Germany) with 12-channel head coil. Design of the study involved language task, bilabial nouns in (active phase) and single letters in (baseline phase) during a single scan. In active phase girl was administered to speak out the general bilabials noun (words) and memory task involved pictures (house hold things, water bodies, land scapes, fruits and vegetables) and patient was instructed to remember pictures and to give response. The stimuli were presented using MR compatible audio visual stimulus system with binocular LCD goggles (Nordic Neuro Lab, Norway), responses were recorded using 4-key button pad (Lumina LP 400, Cedrus Inc, USA) and microphone. (Number of slices: 29, slice thickness 4.5 mm; TR: 4520 ms, TE: 41 ms, FOV: 230 mm, Number of resolution: 64 x 64) was used for the BOLD sessions. Pre- and post-processing was carried out using SPM8 (Wellcome Department of Cognitive Neurology, London, UK). The BOLD clusters were converted from MNI template to the Talairach and Tornoux coordinates, for estimation of anatomical areas.

Results: During language task **Pre surgery:** In study 1 during semantic naming task, Bold activation was observed in left middle frontal gyrus (MFG, BA46), superior temporal gyrus (STG, BA22) however fusiform gyrus (FG, BA19) and inferior frontal gyrus (IFG, BA 47) were active in right hemisphere. **Post surgery :** Middle frontal gyrus, superior temporal gyrus and superior parietal lobule were found active in left hemisphere however lingual gyrus was active contra lateral as compare to preoperative session, Precentral gyrus was strongly active in right hemisphere during semantic noun naming task. During Memory task **Pre surgery:** Middle frontal gyrus (MFG, BA 10) superior frontal gyrus (SFG, BA9), lingual gyrus (LG BA17) and superior parietal lobule (BA7) were active in left hemisphere even Bold activation was observed in middle frontal gyrus (MFG, BA6) and inferior parietal lobule (IPL, BA40) in right hemisphere during visual memory task. **Post surgery:** Activated regions (superior parietal lobule (BA7), middle occipital gyrus (BA 19) post central gyrus (BA3) and middle frontal gyrus (BA10) were lateralized in left hemisphere however fusiform gyrus (BA20) and parahippocampal gyrus (BA27) were surprisingly active in right hemisphere during visual memory task.

Discussion: In our results fMRI study demonstrated the great plasticity of the child's brain and the ability of right hemisphere to take over some expressive language functions during presurgical evaluation whereas it is reorganised after surgery as similar studies (1,3). In this fMRI study of language and memory we could compare for the first time pre and postoperative data of language and memory networks in a child who had normal language development before undergoing complete disconnection of the dominant left hemisphere for severe epilepsy at age 9 years. The isolated right hemisphere was shown able to sustain late plasticity changes for language and memory, thus indicating that it would be reasonable to consider surgical disconnection of the dominant hemisphere at least until 9 years of age in patients with intractable late onset seizures. Postoperative language fMRI studies demonstrated the redistribution of activated areas in the right hemisphere mostly involving regions in which no activation was detectable before surgery but were homologous with those found previously in the left hemisphere.

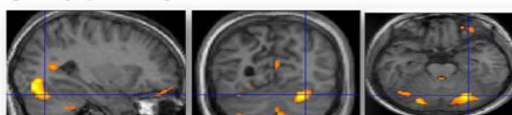
Conclusion: Intractable epilepsy can cause cognitive function developments in a child's brain in which hemispherotomy is a surgical procedure of hemispheric disconnection that has a low rate of complications and seems to be as safe as other procedures for epilepsy surgery and fMRI is a helpful tool for detect language and memory functions in intractable epilepsy patient to give safe treatment.

References: 1. Margaret B. Pulsifer, Jason Brandt, and Cynthia F. Salorio et al, The Cognitive Outcome of Hemispherectomy in 71 Children Epilepsia, 45(3):243-254, 2004.

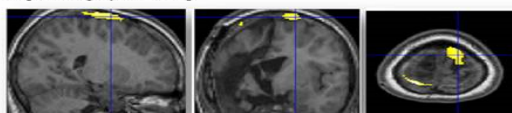
2. Chandra PS, Tripathi M, Hemispherotomy for intractable epilepsy, Neurology, India, 2008 (56) 2.

3. Binder JR, Frost JA, Prieto T, Human Brain Language Areas Identified by FMRI, Neuroscience 1997;17(1), 353-362

Picture1. Bold activation overlaid on axial, coronal and sagittal views as presurgery follow up

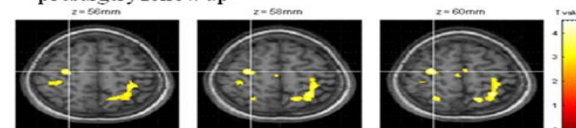


Picture2. Bold activation overlaid on axial, coronal and sagittal views as postsurgery follow up

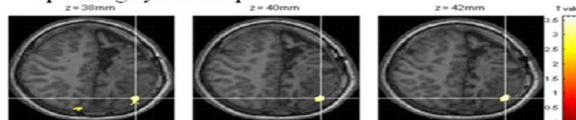


Bold activation in picture 1 & 2 during semantic noun naming task

PictureA. Bold activation overlaid on axial view as presurgery follow up



PictureB. Bold activation overlaid on axial view as postsurgery follow up



Bold activation in Picture A & B, during visual memory task