

RADcommunicator, an iPad application for PI-RADS reporting of prostate multiparametric MRI

Ara Alconchel Pilar¹, Sarah Alessi¹, Michele Colombi², Paul Summers¹, Massimo Bellomi^{1,3}, Luca Antiga², and Giuseppe Petralia¹
¹European Institute of Oncology, Milan, MI, Italy, ²Orobix S.r.l., Bergamo, BG, Italy, ³University of Milan, Milan, MI, Italy

Background: Since its publication in the 2012 ESUR guidelines,¹ the PI-RADS (Prostate Imaging Reporting And Data System) scoring of prostate Multiparametric MRI (mp-MRI) is increasingly used in radiological practice.

RADcommunicator, a freely-available iPad application that facilitates the use of PI-RADS classification for structured reporting of prostate mp-MRI and optimizes the communication of derived results.

Methods: The ESUR guidelines for mp-MRI prostate reporting define distinct five-point scales of criteria for assessing T2-weighted images, diffusion weighted images and dynamic contrast enhanced MRI as well as optionally spectroscopy for each lesion. Each lesion is further given an overall PI-RADS score for the likelihood of clinically significant cancer on a five point Likert-scale. The guidelines also recommend presentation of the report using a structured reporting scheme, which consists of the PI-RADS, graphical presentation of location, and notes on probability of extra-prostatic disease and pertinent incidental findings.

RADcommunicator was developed by the European Institute of Oncology – IEO (Milan, Italy) and Orobix S.r.l. (Bergamo, Italy) to provide a data recording and presentation mechanism in keeping with the ESUR guidelines. The app is freely-available from the iTunes App Store.

RADcommunicator includes a standardized prostate reporting scheme (three axial sections: base, mid-gland and apex - subdivided into a total of 27 regions, and a coronal section of the prostate) on which the radiologist manually draws lesions (Figure 1 upper).

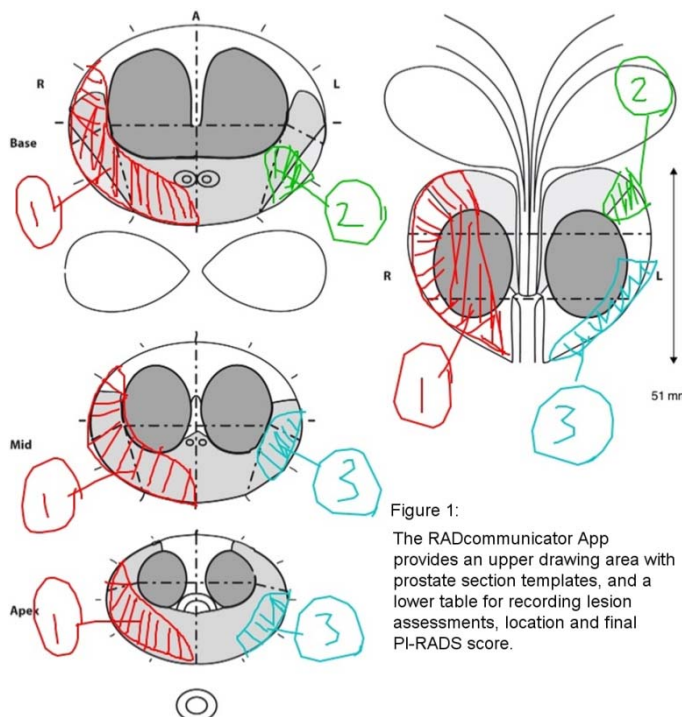
Recording of mp-MRI assessments of each lesion, along with size, site and final PI-RADS score are contained in a table linked to the scheme (Figure 1 lower).

The completed reporting scheme can be forwarded to the referring physician/urologist by email and saved locally to the iPad and/or to a patient information server.

Experience: In our institution, the completed RADcommunicator schemas have been well accepted by other physicians, and forms a basis both for communication between clinical specialists and researchers. To date, over 300 patients have been reported using the scheme. Examples of use include: providing the urologist location information to guide robotic-assisted radical prostatectomy, and target biopsy; selecting sites for intra-operative frozen section analysis by the pathologist, which has led to a significant reduction in positive surgical margins, as well as to match pathology images to mp-MRI for research purposes. The digital record, when combined with a suitable database structure can further assist in integrating the patient record and accessing such information as lesion location and PI-RADS score.

Conclusion: In our experience, RADcommunicator has facilitated routine use of PI-RADS scoring system and enhanced the communication of clinical results from prostate mp-MRI to all physicians involved prostate cancer patient care.

References: ¹ Barentsz JO, Richenberg J, et al. ESUR prostate MR guidelines 2012. Eur Radiol.2012;22(4):746-57.



| LESION | SIZE | SITE | DISTANCE TO APEX [mm] | T2WI | DWI | DCE | CONTACT WITH CAPSULE | PIRADS |
|--------|------|------|-----------------------|------|-----|-----|----------------------|--------|
| 1 | 30 | PZ | 0 | 5 | 5 | 5 | yes | 5 |
| 2 | 10 | PZ | 29 | 4 | 4 | 3 | yes | 4 |
| 3 | 10 | PZ | 0 | 4 | 4 | 4 | yes | 4 |

Notes: TZ 44x36x40mm, LN dubbio 6x8mm iliaco est dx (posteriore a vena, appena sotto biforcazione)