

# Predicting Treatment Response in Non-Small Cell Lung Cancer Patients using mean ADCs and Functional Diffusion Maps

Carolin Reischauer<sup>1,2</sup>, Johannes M. Froehlich<sup>1</sup>, Miklos Pless<sup>2</sup>, Christoph A. Binkert<sup>2</sup>, Sebastian Kos<sup>1</sup>, and Andreas Gutzeit<sup>1,3</sup>

<sup>1</sup>Institute of Radiology and Nuclear Medicine, Clinical Research Unit, Hirslanden Klinik St. Anna, Lucerne, Switzerland, <sup>2</sup>Department of Radiology, Cantonal Hospital Winterthur, Winterthur, Switzerland, <sup>3</sup>Department of Radiology, Paracelsus Medical University, Salzburg, Austria

## Target Audience

MR physicists, radiologists, and oncologists interested in oncologic imaging, in particular monitoring of treatment response to chemotherapy.

## Purpose

The aim of the present study was to evaluate whether diffusion-weighted imaging (DWI) and functional diffusion maps (fDMs) allow predicting treatment response to chemotherapy based on RECIST 1.1 criteria<sup>1</sup> in patients suffering from non-small cell lung cancer.

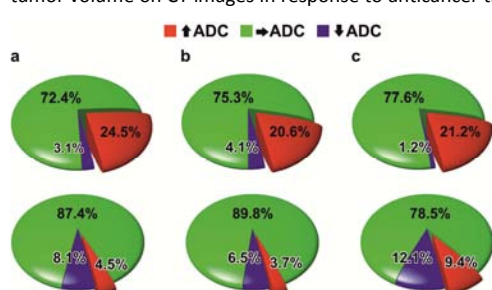
## Methods

**Study Population:** Nine patients (mean age, 66 years; range, 53 – 76 years, 5 females, 4 males) with overall 13 measurable lung tumors were included. The study was approved by the institutional review board and informed written consent was obtained from all patients. The diagnosis of lung cancer was confirmed within 14 days of the baseline MR examination using computed tomography (CT). In all patients diagnosis was histologically proven with transbronchial biopsy. Therapeutic response was determined by evaluating changes in tumor size on CT images after 2 standardized courses of chemotherapy.

**Data Acquisition:** MRI was performed at a maximum of 7 days before treatment begin and repeated at 1, 2, and 6 weeks after onset of the first course of chemotherapy. Imaging was performed on a 1.5 T MR scanner (Achieva, Philips Healthcare, Best, the Netherlands) using a 16-element torso coil. Axial anatomical imaging was performed together with navigator-triggered DWI, using 3 b-values ranging from 100 to 800 s/mm<sup>2</sup>. The lower b-value was chosen to minimize perfusion effects<sup>2</sup>. During the first scan session the DWI scan was repeated once to allow for the calculation of the thresholds for the fDMs.

**Data Analysis:** Data analysis was performed using in-house software written in Matlab (The Mathworks, Natick, MA, USA). First, eddy current-induced image warping was corrected<sup>3</sup>. Second, apparent diffusion coefficient (ADC) maps were calculated using a mono-exponential fit of all b-factor images. This resulted in 5 ADC maps per patient, two pretreatment as well as 3 posttreatment ADC maps. Due to the rapid change in tumor size, regions of interest were defined across all lesions for each examination separately. Care was taken to exclude cavernous areas and atelectatic lung. Thereafter, the mean ADC of each lesion at every time point was calculated. For fDM analysis, all ADC maps were coregistered to the first pretreatment ADC map for each patient individually<sup>4</sup>. Thereafter, the thresholds for the fDMs were calculated as the repeatability limit of the tumor tissue in each patient determined using the two pretreatment ADC maps and one-way analysis of variance (ANOVA)<sup>5</sup>. Beyond the significance threshold, a cluster size threshold was set<sup>5</sup>. In doing so, the percentage of voxels that showed a significant increase (red), a significant decrease (blue) or no change (green) in their ADCs at each posttreatment time point relative to the pretreatment values was computed for each and every lesion in the study cohort (see Figure 1).

**Statistical Analysis:** Statistical analysis was performed with SPSS (IBM Corporation, Armonk, NY, USA). Wilcoxon signed-rank test was used to evaluate changes in tumor volume on CT images in response to anticancer treatment. Timecourses of the mean ADCs over time and percentages of red (significant ADC increase) and blue voxels (significant ADC decrease) at 1, 2, and 6 weeks after treatment onset were analyzed on a per-lesion basis using repeated measures ANOVA. Thereby, the absolute tumor volume and its changes, respectively, were entered as covariates.



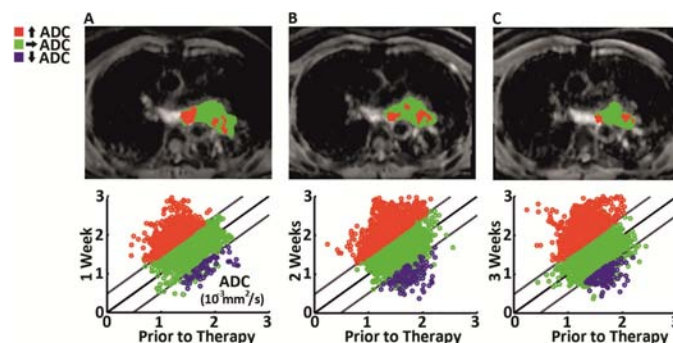
**Figure 2:** Percentages of red (significant ADC increase), green (unchanged ADC), and blue voxels (significant ADC decrease) averaged over all lesions in the study cohort showing large (first row) and moderate (second row) changes in tumor volume on CT images at a: 1 week, b: 2 weeks, and c: 6 weeks after chemotherapy initiation.

## Discussion and Conclusion

The present study indicates that the percentage of red voxels (significant ADC increase relative to pretreatment values) on fDMs allows predicting changes in tumor size under chemotherapy in patients suffering from non-small cell lung carcinoma. Future studies including larger patient cohorts are needed to validate the results.

## References

- <sup>1</sup>Eisenhauer EA, Therasse P, Bogaerts J, et al. New response evaluation criteria in solid tumours: revised RECIST guideline (version 1.1). *Eur J Cancer*. 2009;245:228-247.
- <sup>2</sup>Padhani AR, Liu G, Koh DM, et al. Diffusion-weighted magnetic resonance imaging as a cancer biomarker: consensus and recommendations. *Neoplasia*. 2009;11(2):102-125.
- <sup>3</sup>Netsch T, van Muiswinkel A. Quantitative evaluation of image-based distortion correction in diffusion tensor imaging. *IEEE Trans Med Imaging*. 2004;23(7):789-798.
- <sup>4</sup>Nestares O, Heeger DJ. Robust multiresolution alignment of MRI brain volumes. *Magn Reson Med*. 2000;43(5):705-715.
- <sup>5</sup>Reischauer C, Froehlich JM, Koh DM, et al. Bone metastases from prostate cancer: assessing treatment response by using diffusion-weighted imaging and functional diffusion maps-initial observations. *Radiology*. 2010;257(2):523-531.



**Figure 1:** Example of fDMs defined at a single level through one lesion superimposed onto the corresponding ADC maps (first row) and scatterplots of pretreatment versus posttreatment voxel ADCs over the entire tumor (second row) at A: 1 week, B: 2 weeks, and C: 6 weeks after initiation of chemotherapy.

## Results

Wilcoxon signed-rank test showed a significant decrease of the tumor volumes ( $p < 0.001$ ) at 6-8 weeks after chemotherapy initiation (mean size, 2.8 cm; range, 0.7 – 7.3 cm) with respect to the pretreatment volumes (mean size, 3.7 cm; range, 1.4 – 9.3 cm). Repeated measures ANOVA showed neither a significant change of the mean ADCs over time ( $p = 0.240$ ) nor a dependence of the mean ADCs on the tumor volume ( $p = 0.370$ ). Furthermore, repeated measures ANOVA indicated no significant change of the percentage of red voxels over time ( $p = 0.180$ ). However, it revealed a significant dependence of the percentage of red voxels on the tumor volume change ( $p = 0.002$ ). To understand this dependence, the tumor volume change was entered as between-subjects factor. Thereby, each lesion was classified as either showing moderate ( $< 25\%$ ,  $n = 9$ ) or large decrease in tumor size ( $> 40\%$ ,  $n = 4$ ) under chemotherapy. This analysis showed that the percentage of red voxels was significantly higher in lesions with a large reduction in tumor volume on CT images after 6-8 weeks ( $p = 0.041$ ). Thereby, the differentiation between lesions with moderate and large tumor volume changes was highest at 1 week after treatment onset (see Figure 2). Finally, repeated measures ANOVA showed neither a significant change of the percentage of blue voxels over time ( $p = 0.070$ ) nor a dependence of the percentage of blue voxels on the tumor volume change ( $p = 0.181$ ).