

3D Fractal Analysis of Pulmonary MRA distinguishes Pulmonary Arterial Hypertension Patients from Normal Volunteers

Phillip Kilgas¹, Eric Schrauben², Alejandro Roldan-Alzate¹, Oliver Wieben², Naomi Chesler³, Christopher François¹, and Mark L. Schiebler¹

¹Radiology, UW-Madison, Madison, WI, United States, ²Medical Physics, UW-Madison, Madison, WI, United States, ³Biomedical Engineering, UW-Madison, Madison, WI, United States

PURPOSE: Pulmonary arterial hypertension (PAH) is a rapidly progressive disease. As a result of elevated pulmonary arterial pressures, pruning of the number of small pulmonary artery occurs [1]. Quantification of this pruning may provide a biomarker independent of vessel size for this disease and could lessen the need for invasive catheter based measurements. Previous computed tomography (CT) studies have used the quantitative method known as fractal analysis for diagnosing PAH in 2D projections [2]. The objective of this study was to implement 3D fractal analysis using MRA images of the pulmonary arterial tree to quantify the morphological differences between PAH patients and healthy volunteers.

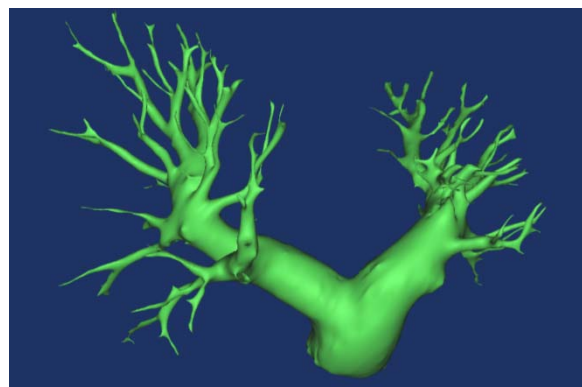


Fig. 1: Anatomical image of a PAH patient's pulmonary arterial tree.

METHODS: With IRB approval and HIPAA compliance, informed consent for eight PAH patients and eight healthy volunteers were obtained. All non-gated MRA exams were acquired at 3T (GE Healthcare, Waukesha, WI) following the administration of gadolinium-based contrast agent at 1.5 ml/sec (gadobenate dimeglumine, Bracco, Milan). Scan parameters of the SPGR sequence included TR/TE of 2.9/1.0 ms, average field of view = 34 x 27 cm, slice thickness = 2.0 mm, 140-160 slices, flip angle = 28°, and acquired spatial resolution of 1.3 x 1.8 x 2.0 mm³, which was interpolated to 0.7 x 0.7 x 1.0 mm³ by 2D homodyne [3,4]. Breath-hold time range was 15-21 seconds. Post-processing was evaluated using magnitude images in visualization software (Mimics, Materialise, Belgium) to define the pulmonary arterial tree for quantification (Fig. 1). Once segmented, fractal dimension (FD) analysis was calculated through additional commercial software (Matlab, MathWorks, MA, USA) to assess morphological complexity between PAH patients and healthy volunteers [5]. Fractal analysis, a mathematical technique, utilizes a box-counting method to differentiate morphology (Fig. 2).

Box-counting systematically lays a series of grids of decreasing box sizes (start with a single box equal to the size of the image volume and reduce by a factor of two at each step) over a reconstructed 3D image of the pulmonary arterial tree and records data (the counting) for each successive box. Count represents the number of boxes in each grid that had any part of the important detail of the image in them, in this case the segmented vascular tree. FD is estimated by the slope of the log-log plot of box count versus box size. As box size decreases, count progressively increases. Differences in these measurements were statistically analyzed using a paired Student's t-test.

	Fractal Dimension
PAH Patients:	1.824 ± 0.05
Volunteers:	1.776 ± 0.03
P-value:	0.044

Table 1: Summarized results for PAH patients and healthy volunteers. Fractal Dimension considered significantly different ($P \leq 0.05$).

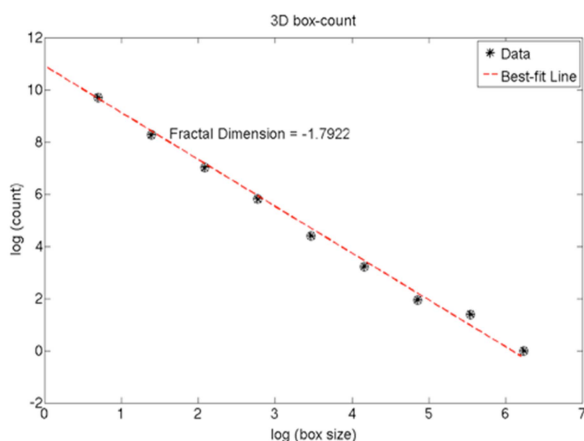


Fig. 2: Graph results from 3D box-counting method. Count increases as box size decreases.

RESULTS AND DISCUSSION: Excellent 3D representation in the pulmonary arterial tree (Fig. 1) permits visualization of very small arteries. Box-counting and linear regression (Fig. 2) allows for automated calculation of FD from the 3D segmented volume. Table 1 summarizes FD (mean ± standard deviation) measurements between PAH patients and healthy controls. In agreement with previous studies, PAH patients had significantly ($p \leq 0.05$) higher FD. Compared to previous studies employing CT and calculating FD from a 2D projection (potentially missing portions of the arterial tree) [2], the use of MRA eliminates the use of ionizing radiation while performing FD analysis on an entire 3D volume. The more accurate representation of the tree in 3D likely permits more accurate estimates of FD, though further research must be performed for comparison.

CONCLUSION: 3D fractal analysis of the pulmonary arterial branching pattern, derived from MRA examinations, is an independent variable that can be used to diagnose the presence of pulmonary arterial hypertension.

ACKNOWLEDGEMENT: We gratefully acknowledge funding by NIH: HL105598, HL115061

REFERENCES: 1. Moledina et al. *Heart* 2011;**97**:1245-1249 2. Haitao et al. *KJR* 2011;**12(3)**:289-296. 3. Lum et al. *JMRI* 2009. 4. Brau et al. *MRM* 2008. 5. Reishofer et al. *PLoS One* 2012;**7(7)**:e41148.