

# Free-breathing Myocardial Perfusion Imaging using Respiratory Binning

Johannes F. M. Schmidt<sup>1</sup>, Lukas Wissmann<sup>1</sup>, and Sebastian Kozerke<sup>1,2</sup>

<sup>1</sup>Institute for Biomedical Engineering, University and ETH Zurich, Zurich, Switzerland, <sup>2</sup>Imaging Sciences and Biomedical Engineering, King's College London, London, United Kingdom

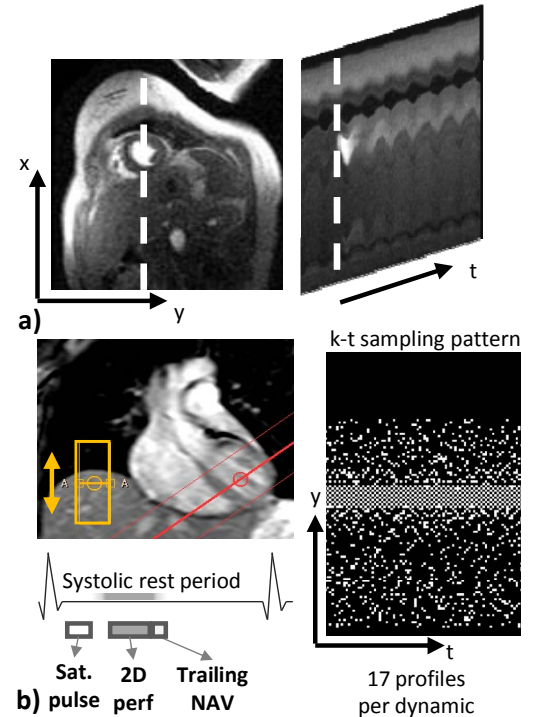
**Introduction:** In dynamic contrast-enhanced myocardial perfusion imaging, scan acceleration methods are invaluable to meet the demands on spatial resolution and cardiac coverage [1]. Temporally constrained image reconstruction of highly undersampled k-space data is sensitive to respiratory motion [2], but breathholding or shallow breathing cannot be ensured under all circumstances in clinical routine exams.

In the present work, undersampled free-breathing myocardial perfusion data is sorted into five respiratory bins and each bin is reconstructed separately. The maximum breathing amplitude in each respiratory bin is limited. Further image registration can be performed in image domain using the high-resolution data set including all respiratory bins.

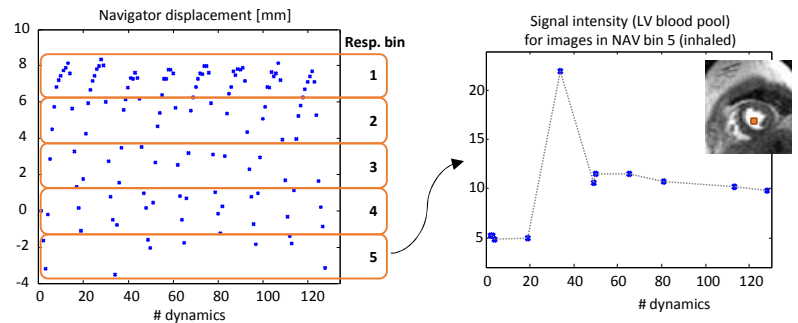
**Methods:** Two-dimensional perfusion data were acquired on a Philips 1.5T Achieva system (Philips Healthcare, Best, The Netherlands) with a 5-channel cardiac coil array, using a saturation-recovery gradient echo sequence triggered to end systole. Scan parameters were: TR: 2.2ms, TE: 1.1ms, flip angle: 15°, spatial resolution: 2.3x2.3mm<sup>2</sup>, 128 time frames, acquisition matrix: 120x119, partial Fourier factor: 0.75, saturation delay: 150ms. A contrast bolus of 0.05 mmol/kg b.w. of gadolinium (Gadovist, Bayer Schering, Berlin, Germany) was applied. The respiratory phase was estimated using a trailing pencil-beam navigator. K-space data were retrospectively undersampled with a time-interleaved k-t sampling with a regularly undersampled k-space center and increasingly incoherent random sampling for higher phase encodes (Fig. 1) to achieve a reduction factor of 7. Image reconstruction was performed with an iterative thresholding algorithm upon transformation into a sparse transform domain using the temporal Fourier transform and subsequent principal component analysis (PCA). The iterative update rule is given by  $\mathbf{x}_{n+1} = \Phi^{-1}P\Phi(\mathbf{x}_n - \mathbf{E}^H(\mathbf{E}\mathbf{x}_n - \mathbf{d}))$  where  $\mathbf{E}$  denotes the encoding matrix,  $\mathbf{d}$  the acquired k-space data,  $\mathbf{x}_n$  the image estimate at iteration  $n$ , and  $\Phi = B_{f \rightarrow pc} F_{t \rightarrow f}$  the sparse transform. For binned image reconstruction, k-space data were sorted into five respiratory bins according to the displacement as measured with the trailing pencil-beam navigator. A PCA basis transformation was obtained per respiratory bin from a low-resolution TSENSE reconstruction [4] of the k-space center. Note that the discontinuities in the signal intensity due to the non-uniform time steps (Fig. 2) do not have sparse representations in the temporal Fourier or finite differences domain, therefore requiring data dependent transforms such as a principal component analysis. After reconstruction of each respiratory bin, the images were resorted according to their original order in time. Image reconstruction without respiratory binning was performed for reference using a PCA basis comprising of all respiratory bins.

**Results:** Image reconstruction results comparing the binned reconstruction and reconstruction without respiratory binning are presented in Figure 3. Signal intensity-time curves for the binned reconstruction were found to be comparable with the fully sampled reference while residual motion artifacts are present in the reconstruction without binning.

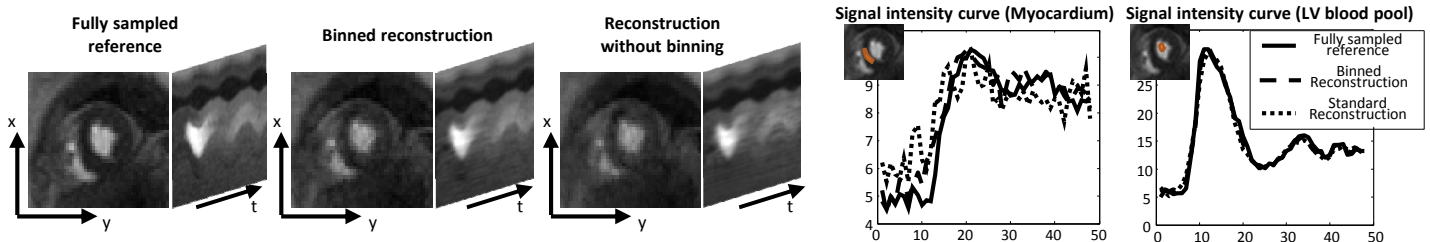
**Discussion:** Respiratory motion artifacts in free-breathing myocardial perfusion imaging can be suppressed by sorting of k-space data into respiratory bins and individual reconstruction for each respiratory state. The scan time penalty for acquiring more dynamics to ensure a sufficient amount of data in each respiratory bin is small compared to the re-acquisition of perfusion data including delays for contrast agent washout.



**Figure 1:** Free-breathing first-pass myocardial perfusion images were acquired for 128 time frames with a trailing pencil-beam navigator for respiratory motion detection.



**Figure 2:** K-space data is sorted according to the pencil beam displacement into five respiratory bins (left). The non-uniform time steps provoke abrupt changes in the signal intensity curves in each respiratory bin.



**Figure 3:** Image reconstruction results showing 48 dynamics of the first passage of the contrast agent (left) for the fully sampled reference, the binned reconstruction, and conventional image reconstruction without respiratory binning. Signal intensity-time curves using a frame-by-frame segmentation mask for myocardium and left ventricular (LV) blood pool are presented in the graphs (right).

**References:** [1] Kellman P, MRM (51), 2004, [2] Vitanis V, MRM (65), 2011, [3] Daubechies I, Comm. Pure Appl. Math. (LVII), 2004, [4] Kellman P, MRM (45), 2001