

## Radiation-induced myocardial injury visualized by LGE-MRI

Brent D. Wilson<sup>1,2</sup>, Alexis Harrison<sup>1,2</sup>, Yu-Huei J. Huang<sup>3</sup>, Kavitha Damal<sup>2</sup>, Nathan S. Burgon<sup>2</sup>, Mark M. Haslam<sup>2</sup>, Martha J. Glenn<sup>3</sup>, David K. Gaffney<sup>3</sup>, Bill J. Salter<sup>3</sup>, Nassir F. Marrouche<sup>1,2</sup>, and Christopher J. McGann<sup>1,2</sup>

<sup>1</sup>Cardiovascular Center, University of Utah, Salt Lake City, Utah, United States, <sup>2</sup>Comprehensive Arrhythmia Research and Management Center, University of Utah, Salt Lake City, Utah, United States, <sup>3</sup>Huntsman Cancer Institute, University of Utah, Salt Lake City, Utah, United States

### Target Audience

Oncologists and imaging professionals caring for patients with malignancies treated with external beam radiation therapy (EBRT).

### Purpose

Advances in cancer treatment with multi-agent chemotherapy in combination with EBRT have led to increased survivorship; however, a complication hampering prognosis is radiation-induced heart disease, which has been difficult to assess. Recent advances in LGE-MRI technology allow us to visualize and quantify the extent of atrial tissue injury after radiation exposure. We evaluated the utility of late gadolinium enhancement (LGE) magnetic resonance imaging to identify atrial injury secondary to EBRT and the correlation between extent of tissue damage and dose of EBRT administered.

### Methods

Eleven patients with a history of lymphoma treated with thoracic EBRT (8.92±11.84 years prior) were compared to gender-matched controls with no history of EBRT therapy. Imaging was performed on a 3-Tesla MRI scanner (Verio, Siemens). Evaluation of the atria was performed using a 3D respiration-navigated, inversion recovery prepared gradient echo pulse sequence (1, 2). Evaluation of 3D LGE images of the cardiac atria was performed utilizing image analysis software (Corview, MARREK). Oncologic treatment plans were available in our treatment planning system (TPS) (Eclipse 10.0, Varian Medical Systems). We imported 3D LGE-MRI with our delineated atrial walls into the TPS. The 3D CT images taken at the time of simulation (used for treatment planning purpose) were non-deformably registered with the masked 3D LGE-MRI, resulting in an MR/CT registered image focused on the heart with the LA wall as our region of interest. After identifying LA scar and LA wall, radiation doses to these structures were recalculated on the planning CT. In the TPS, the doses received by both structures were visualized in different viewing planes (transverse, coronal, and sagittal) (Figure 1). Radiation dose-volume histograms from patient-specific EBRT treatment plans were correlated with distribution of LGE in the atria.

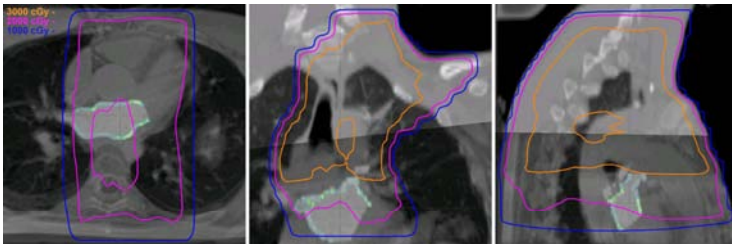


Figure 1. Blended CT/MRI with scar and radiation dose lines.

### Results

We did not see a statistically significant difference between LVEF or atrial measurements in patients with a history of EBRT versus control subjects ( $p > 0.05$  in all cases). We also found no evidence of focal LV LGE in any of the patients who received EBRT. The extent of LGE as a relative percentage of the total LA area was significantly greater in patients with a history of


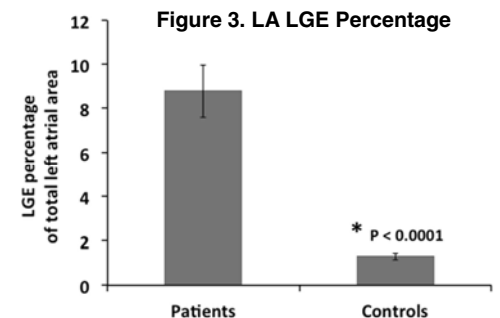


Figure 2. LA LGE in patients with and without EBRT

EBRT than control subjects who had never been treated with EBRT (8.8±3.6% versus 1.5±0.6%,  $P < 0.0001$ ; Figures 2 and 3). We conducted secondary analysis excluding two patients who received EBRT over 10 years ago prior to implementation of modern shielding improvements, and we still found a significantly greater percentage of LA LGE in the remaining eight patients who have received EBRT within the last 10 years when compared to sex-matched control subjects (7.3 ± 1.1% versus 1.3 ± 0.5%,  $P < 0.00001$ ). There was no correlation between the percentage of LA LGE and time since radiation in the patients who received EBRT in the past 10 years ( $r = -0.09$ ,  $p = 0.81$ ).



### Discussion

In this study, we investigated the use of LGE-MRI to detect radiation-induced injury in cardiac tissue and found a significantly greater degree of sub-clinical myocardial injury in patients who underwent EBRT for lymphoma treatment regardless of the length of time since irradiation. This injury was evident as focal LA injury. Though there are differences between the treatment and the control groups besides RT (e.g. treatment group received chemotherapy in addition to RT), co-localizing LGE-MRI with radiation dose distributions from individual patient's EBRT-TPS clearly displays a congruence between spatial distribution of RT-induced scar and dose of radiation leading us to postulate that the myocardial injury was acquired secondary to incidental exposure to radiation.

To our knowledge, this is the first study that has utilized LGE-MRI to detect structural myocardial changes following EBRT. Cardiac MRI identifies subclinical injury months after EBRT and also shows a dose-dependent pattern of injury. LGE-MRI based tissue remodeling detection has been shown to be highly sensitive and reliable in multiple cardiac pathologies. Our data suggest that radiation-induced myocardial damage can be reliably quantified using the novel LGE-MRI technique.

### Conclusions

Our results show that LGE-MRI can detect radiation-induced myocardial tissue injury and that tissue injury correlates with dosage of EBRT. Imaging myocardial injury resulting from radiation using MRI may be a useful modality to follow cardiac toxicity from EBRT and identify individuals who are more susceptible to radiation CV damage. In addition, LGE-MRI may identify those who need long-term monitoring for cardiac complications of radiotherapy.

### References

1. McGann CJ, Kholmovski EG, Oakes RS et al. New magnetic resonance imaging-based method for defining the extent of left atrial wall injury after the ablation of atrial fibrillation. *J Am Coll Cardiol* 2008;52:1263-71.
2. Oakes RS, Badger TJ, Kholmovski EG et al. Detection and quantification of left atrial structural remodeling with delayed-enhancement magnetic resonance imaging in patients with atrial fibrillation. *Circulation* 2009;119:1758-67.