

Evaluation of patients of the cerebral vasculature: Comparison with Silenz MRA and 3D TOF MRA.

Kenichi Mizuki¹, Takayuki Masui¹, Motoyuki Katayama¹, Kimihiko Sato¹, Kei Tsukamoto¹, Nami Matsunaga², Miyoshi Mitsuharu², Hiroyuki Kabasawa², and Harumi Sakahara³

¹Seirei hamamatsu general hospital, hamamatsu, shizuoka, Japan, ²GE healthcare, Tokyo, Japan, ³Hamamatsu university school of medicine, shizuoka, Japan

Target Audience: The scientists, physicians, and technologists who are interested in MR angiography for cerebrovascular diseases with focus of comfortable MR imaging.

Introduction: Three-dimensional time-of-flight MR angiography(3D TOF MRA) has widely used for evaluation of intracranial arteries as non-invasive technique. Recently developed MR Silent Scan (Silenz, GEHC) is designed to almost eliminate acoustic noise to an ambient sound level by reducing rapid gradient switching using ultrashort TE (almost zero msec). This technique is applied to MRA of the intracranial arteries. In Silenz MRA, a continuous RF inversion pulse is applied to the blood around the carotid bifurcation and the data are collected with Silent technique. As a control, the long RF inversion pulse is applied above the head to minimize magnetization transfer effects and data were collected. These two datasets are subtracted to eliminate the background, demonstrating the entire vasculature in the head. Currently, blood labeling parameters for Silenz MRA were fixed and arteries in normal subjects could be visualized. Accordingly, the purpose of the study was to compare Silenz MRA with fixed parameter with 3D TOF MRA for the evaluation of patients having cerebrovascular diseases.

Methods: This study, approved by IRB in our hospital included 27 consecutive patients (M:F 10:17 mean age, 66 years,)who underwent both Silenz and 3D TOF MRA on a 3T magnet (Discovery 750w, GEHC) using a 12 channel head coil. In preliminary study, we scanned normal subjects for visualization of intracranial arteries in Silenz MRA. Slice thickness, field of view, and position of the scanning areas were adjusted. The parameters for Silenz MRA were TR/TE, 1003-1116/0.016-0.02; ETL, 1; matrix size, 150×150; FOV, 18 cm; slice thickness, 1-1.2 mm; number of the slice,300-400, flip angle, 5°. 3D TOF MRA; TR/TE, 22-23/2.3-2.6; ETL, 1; matrix size, 150×150 or 200×200; FOV, 18 cm; slice thickness, 1.2 mm; number of the slice,140-260, flip angle, 18°). Twenty-one of 27 patients had possible aneurysmal dilatation (28 lesions). Overall image quality and visualization of intracranial vasculature were evaluated, and detection of aneurysms on Silenz MRA with that on 3D TOF MRA using multiplanar volume reformation (MPVR). And uniformity of signal intensity (SI) of carotid artery (two segment; C2-3, C4-5 segment) at siphon was visually assessed. SIs were measured on sagittal MPVR of Silenz MRA and 3D TOF MRA imaging by using a polygonal ROI. Wilcoxon matched-pairs signed-rank test was used to compare standard deviation (SD) / average of signal intensities (Ave(SI)) of Silenz and that of 3D TOF MRA. P values of less than .05 indicated statistical significance.

Results:All 3D TOF MRA and 25 of 27 cases of Silenz MRA were diagnostic. In three cases with Silenz MRA, distal part of right middle cerebral artery and basilar artery, and right anterior cerebral artery decreased in SI, but overall image quality was diagnostic. On the other hand, in two cases with Silenz MRA, distal part of bilateral carotid artery decreased in SI and overall image quality was undiagnostic. 28 aneurysmal lesions in 19 patients were recognized on both MRA(Figure1). Two lesion were missed on Silenz due to failure of visualization of the distal arteries and aneurysm. In diagnostic cases of 25 patients, SIs of vasculatures were visually homogenous in Silenz. SD/Avg(SI) of CS of Silenz MRA was lower than TOF MRA(P<0.05 Figure2).

Discussion: Silenz MRA can be obtained without sounds expected to be heard with regular MRA sequences. With very short TE on Silenz MRA with currently fixed parameters, SIs of the arteries are homogenous, information can be obtained with almost identical to TOF MRA. In some cases on Silenz MRA, visualization on distal arteries and aneurysm was not made provably due to slow flow. In these cases, labeled blood signal might not flow into the distal arteries or aneurysm. Farther optimization of labeling parameter needs to be considered in clinical settings including sever cerebrovascular diseases, which have slow flow velocities

Conclusions: Silenz MRA may provide information of vascular lesions with homogenous SI although farther optimization of parameters for Silenz MRA may be required.

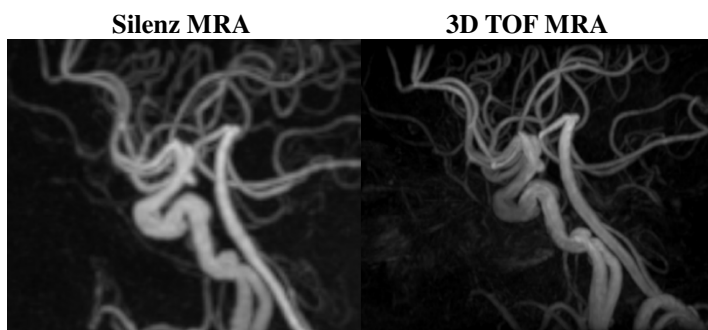


Figure 1 Left IC-PC infundibular dilatation were detectable both on Silenz MRA and 3D TOF MRA

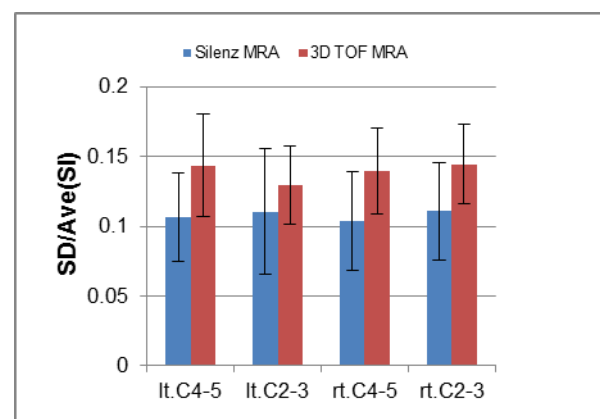


Figure 2 Graph shows SD/Ave of signal intensity of Silenz MRA(blue) and 3D TOF MRA(Red). SD/Ave(SI) values of Bilateral C4-5 segment and C2-3 segment of Silenz MRA were lower than 3D TOF MRA(p<0.05).