

High Resolution Imaging of Peripheral Arteries with 3D Quiescent-Interval Single-Shot (QISS) Non-enhanced Magnetic Resonance Angiography

Huan Tan¹, Shivraman Giri², Ioannis Koktzoglou^{1,3}, and Robert R Edelman^{3,4}

¹University of Chicago, Chicago, IL, United States, ²Siemens Healthcare, Chicago, IL, United States, ³Northshore University HealthSystem, Evanston, IL, United States, ⁴Northwestern University, Chicago, IL, United States

Purpose: Non-enhanced MRA is of growing interest due to the concern for nephrogenic systemic fibrosis in patients with peripheral vascular disease (PVD). Quiescent Interval Single Shot (QISS) MRA (1) is a non-enhanced technique for assessment of lower extremity vasculature that is easy to use, does not require patient specific parameters, and is insensitive to motion, heart rate, and flow patterns (2,3). With a 2D acquisition sequence, the minimum slice thickness achievable (largely determined by the maximum gradient strength) by QISS is limited to about 1mm. In this study, we implemented a 3D bSSFP readout for QISS MRA (3D-QISS) to enable sub-millimeter slice resolution with improved SNR for imaging of the peripheral arteries.

Methods: The acquisition scheme of 3D-QISS is illustrated in Figure 1. Compared with the original QISS method, the main modifications include: a) the 2D bSSFP readout was replaced by a 3D bSSFP readout with center-to-out partial Fourier k-space trajectory and single-shot acquisition along the phase encoding direction. b) fat suppression was implemented using spectral selection attenuated inversion recovery (SPAIR).

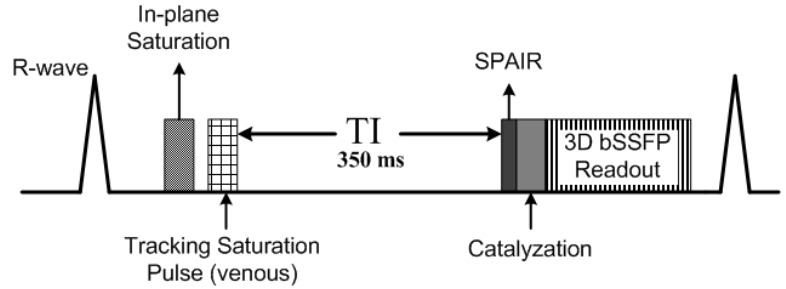


Figure 1. Pulse diagram of 3D-QISS.

Four healthy volunteers (age 28 - 51) were recruited with approval from the local Institution Review Board. Imaging was performed on a 32-channel 1.5T scanner (MAGNETOM Avanto, Siemens HealthCare, Erlangen, Germany). 3D-QISS (slice thickness = 0.3mm), 2D-QISS (slice thickness = 3mm), and thin-slice 2D-QISS (slice thickness = 1.2mm) were acquired for comparisons. Imaging orientation was axial and in-plane resolution was 1x1mm. ECG gating was used to ensure inflow during systole and data acquisition during diastole. The inversion time was 350ms for all sequences. A tracking saturation pulse was used to suppress the veins, GRAPPA = 2 along the phase encoding direction, 5/8 partial Fourier. 3D-QISS specific imaging parameters were: 30 slab concatenations per station, encodings per slab = 24, slab distance factor = -25%, slice resolution = 50%. SNR was computed using the magnitude images accounting for the difference in voxel size.

Results: Examples of 2D-QISS, thin slice 2D-QISS, and 3D-QISS are illustrated in Figure 2. Excellent image quality was achieved with 3D-QISS, allowing detailed depiction of the vessel bifurcations compared to 2D-QISS with routine parameters. Less venous contamination was observed with 3D-QISS compared to thin slice 2D-QISS. The SNRs (mean \pm standard deviation) after normalizing for voxel size were 8 ± 0.4 , 22 ± 2.7 , and 32.5 ± 1.6 for 2D-QISS, thin-slice 2D-QISS, and 3D-QISS, respectively (SNRs before normalizations were 24.0 ± 1.2 , 26.4 ± 3.3 , and 19.5 ± 1.0).

Conclusion: 3D-QISS allows for nonenhanced MRA with sub-millimeter slice thickness, which could be helpful for better characterizing stenotic lesions. Venetian blind like artifacts were seen as a result of slab concatenations and imperfect slice profiles. Potential solutions are under investigation. Alternative acquisition trajectory such as stack of stars radial may further improve vessel to background contrast. The clinical utility of the technique requires further investigation.

References: 1) Edelman et. al., MRM, 2011. 2) Hodnett et. al., Radiology, 2011. 3) Hodnett et. al., AJR, 2011.

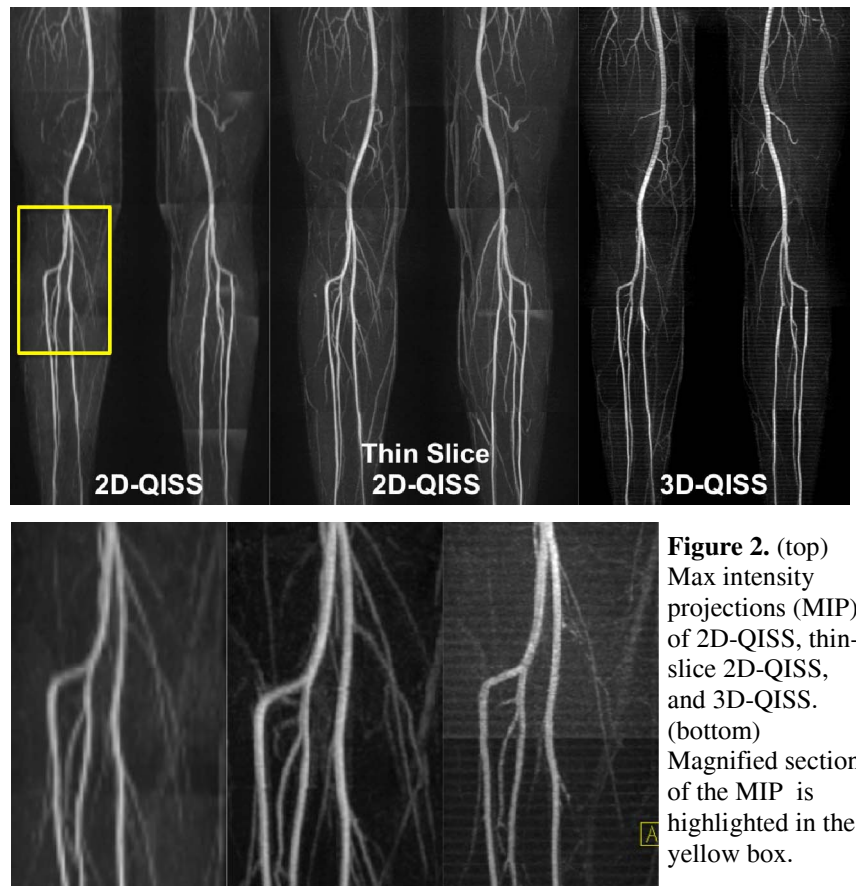

Figure 2. (top) Max intensity projections (MIP) of 2D-QISS, thin-slice 2D-QISS, and 3D-QISS. (bottom) Magnified section of the MIP is highlighted in the yellow box.