

A theranostic approach based on the use of a dual boron/Gd agent to improve the efficacy of Boron Neutron Capture Therapy in the pulmonary metastasis treatment.

Simonetta Geninatti¹, Diego Alberti², Antonio Toppino², Annamaria Deagostino², Stefania Lanzardo², Nicoletta Protti³, Silva Bortolussi³, Saverio Altieri³, and Silvio Aime²

¹Molecular Biotechnology and health sciences, University of Torino, Torino, TO, Italy, ²University of Torino, TO, Italy, ³University of Pavia, PV, Italy

Purpose. This study aims at investigating a new theranostic approach for the treatment of disseminated pulmonary metastasis based on the use of Boron Neutron Capture Therapy (BNCT), a non conventional radiotherapy that combines low energy neutron irradiation with the presence of boron-containing compound at the targeted cells. Neutrons are captured by nonradioactive isotope ¹⁰B that disintegrates into alpha particles and lithium nuclei that cause non reparable damage to the cell where they were generated, sparing the surrounding ones, potentially healthy. This fact makes BNCT a promising option for the treatment of pleura metastasis disseminated in the thoracic cavity that cannot be treated by methods requiring a precise localization, such as surgery or conventional radiotherapy. The innovation of this study lies on the development and test of novel theranostic agents, able to maximize the selective uptake of boron atoms in tumor cells and, at the same time, to quantify the in vivo boron distribution in the tumor and in other tissues by Magnetic Resonance Imaging (MRI). The measurement of local boron concentration is crucial to determine the optimal neutron irradiation time, to calculate the delivered radiation dose and to evaluate the toxicity of the treatment by determining differences in boron concentration between tumor and healthy tissues. Among the compounds developed for BNCT, carboranes are under intense scrutiny for their high boron payload. A new dual BNCT/MRI agent has been synthesized and delivered to tumor cells using Low Density Lipoproteins (LDLs). LDLs have been identified as good carriers of BNCT agents since the expression of LDLs receptors is upregulated in many tumors.

Methods. TUBO breast cancer cells have been used for both “in vitro” and “in vivo” tests. Pulmonary metastasis mouse model have been obtained by injecting 50000 TUBO cells intravenously in syngenic mice. Gd and boron concentrations have been measured by measuring the signal intensity enhancement on T1 weighted images acquired before and after theranostic agent administration BNCT has been performed after MRI analysis at the TRIGA-Mark II reactor at the University of Pavia.

Results. 4h after the administration boron tumor concentration calculated by MRI is 40±10 ppm ca. five-fold higher than in the adjacent tissues. Two groups of animals underwent the irradiation treatment. A third group of non-irradiated mice was used as control to assess tumor grown in the absence of any treatment. With respect to control groups, in boron treated group, tumor growth was significantly slower. The efficacy of the treatment and evaluation of the selective internalization by mammary carcinoma tumor cells has been proved also “in vitro” on cultured cells.

Discussion. This study is a typical example in which a highly selective therapy takes advantages from imaging to improve its efficacy. In fact, the imaging of boron distribution by MRI just before the irradiation permits to be very precise in assessing the treatment plan and dosimetry. The selectivity of BNCT is guaranteed by a differential targeting of the tumor cells rather by the radiation beam as it occurs in conventional radiotherapies. This makes BNCT a promising option for tumors disseminated or characterized by an infiltrative nature that cannot be treated by methods requiring precise localization, such as surgery or radiotherapy. Pulmonary metastases are an example of tumor spreading in the thoracic cavity, whose irradiation involves many radiosensitive organs such as lung, hearth and spine. For this reason is often impossible to deliver a lethal dose to these lesions using conventional radiotherapy.

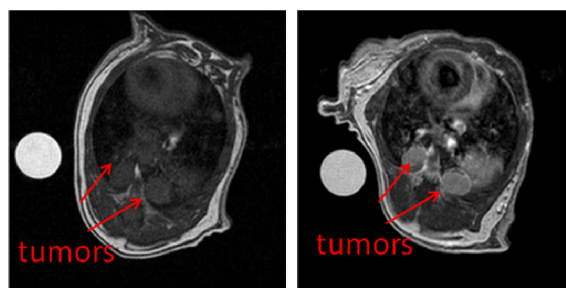


Figure 1. T1weighted MRI image of pulmonary metastases before (left) and after (right) contrast administration

Conclusions. It has been demonstrated that imaging can help BNCT to be more effective and specific in killing tumor cells by sparing healthy ones. In fact, from the signal enhancement generated by the Gd(III) complexes, we access to the key information that the ¹⁰B concentration threshold, necessary to perform irradiation, has been reached. A double treatment to kill remaining Q cells will be carried out to increase treatment performance.