

Monitoring Bone Remodeling Following MR-Guided High Intensity Focused Ultrasound on MRI and CT in a Swine Model

Matthew Bucknor¹, Viola Rieke¹, Loi Do¹, Sharmila Majumdar¹, Thomas Link¹, and Maythem Saeed¹

¹University of California, San Francisco, San Francisco, CA, United States

Purpose: The advent of magnetic resonance guided high-intensity focused ultrasound (MRgHIFU) has signaled a potential paradigm shift in the treatment of focal bone lesions. Of note, both experimental and clinical studies of MRgHIFU for focal bone lesions have demonstrated remodeling of bone in the weeks to months following MRgHIFU, in some instances with apparent new bone growth.^{1,2} Remodeling has been reported both in patients treated for bone metastases¹ and in a preclinical porcine study.² The purpose of the current study was to clearly delineate patterns of bone remodeling following MRgHIFU in a porcine model, as a function of sonication energy.

Methods: All experimental procedures were done in accordance with National Institutes of Health guidelines for humane handling of animals and received prior approval from the local Institutional Animal Care and Use Committee. We performed MRgHIFU using an ExAblate® 2000 system (InSightec, Haifa, Israel) integrated with a 3.0 Tesla MR scanner (GE Healthcare, Waukesha, WI, USA) in the right femur of eight pigs. Multiplanar fat saturated T2-weighted fast spin echo (FSE) and 3D spoiled gradient echo images were acquired for treatment planning. Two discrete ovoid treatment targets were prescribed at each proximal diaphysis and distal metadiaphysis of the right femur. The energy dosed to the distal target was higher (419 ± 19 J) than the proximal target (324 ± 17 J). The other parameters were kept constant with a transducer frequency of 1.05 MHz, sonication duration of 20 seconds, and cooling duration of 25 seconds. Follow-up imaging was performed at 3 and 6 weeks with MRI using T2-weighted FSE (FOV/slice thickness/TR/TE/ETL/flip angle/matrix/BW=36cm/7mm/3500ms/83ms/12/90/256x224/10.4kHz) and delayed postcontrast (0.1 mmol/kg Gd-DTPA at 10 minutes) 3D spoiled gradient echo images (FOV/slice thickness/TR/TE/flip angle=44x44cm/3.8mm/4.3ms/2ms/15). CT imaging was also obtained at 3 and 6 weeks.

Results: MRI bone ablation sizes at 3 and 6 weeks following MRgHIFU were similar between proximal (low energy) and distal (high energy) lesions (average $8.7 \times 21.9 \times 16.4$ mm). A consistent evolution in the imaging appearance was seen in all animals at 3 and 6 weeks (Figure 1). At 3 weeks there was persistent T2 hyperintensity and moderate peripheral enhancement (not shown), particularly in the soft tissues along the lateral cortex of the bone, with slightly increased T2 hyperintensity and enhancement of the distal ablations compared with the proximal ablations. At 6 weeks, distal ablations demonstrated marked cortical irregularity with a small focus of T2 heterogeneity. Proximal ablations were difficult to visualize at this later time point. Finally, on CT, all distal ablations ($n=8$) demonstrated evidence of new bone density along the cortex, with a subtle focus of osseous density at 3 weeks and a larger focus at 6 weeks. New bone density was not seen in any of the proximal ablations at either time point.

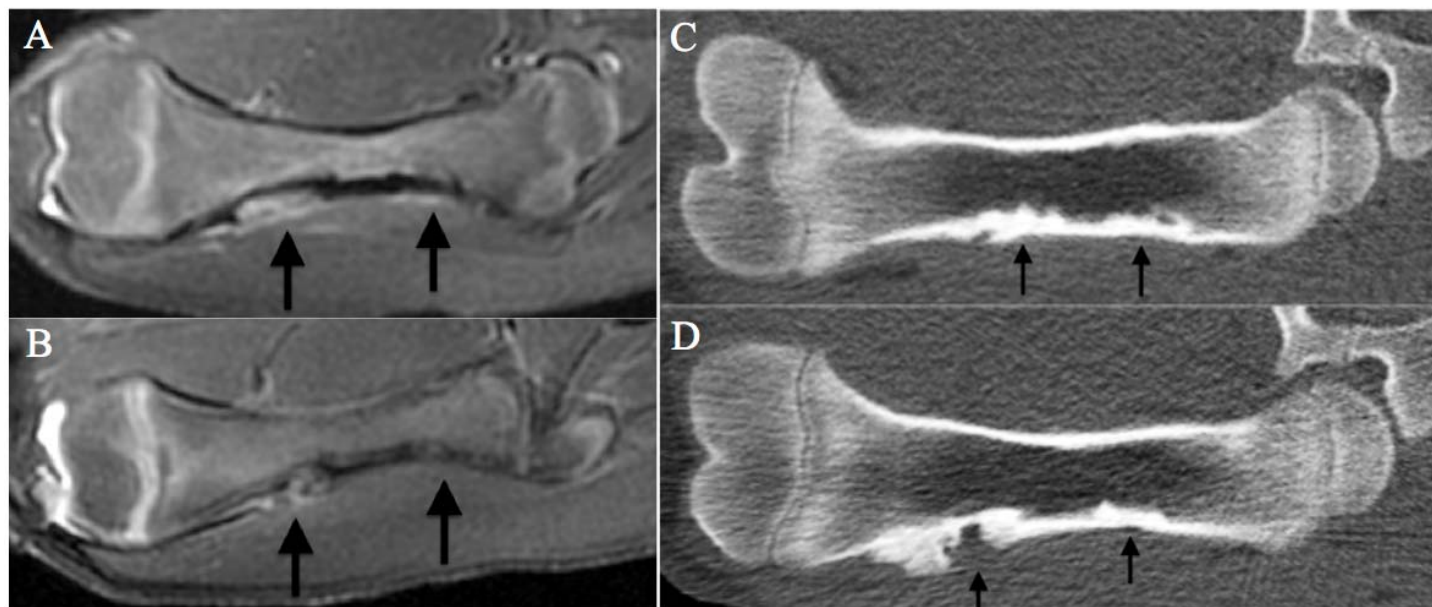


Figure 1. Representative coronal MR and CT follow-up images at 3 and 6 weeks status post MRgHIFU. A) T2-FSE at 3 weeks demonstrates focal T2 hyperintensity distally and subtle hyperintensity proximally. B) At 6 weeks a heterogeneous ovoid focus of T2 hyperintensity is seen and the proximal ablation is difficult to visualize. On CT, both ablations at 3 weeks C) demonstrate mixed endosteal sclerosis and lucency. D) At 6 weeks, there is evidence of new bone density along the distal, high energy lesion and compact endosteal sclerosis at the proximal ablation.

Conclusion: MRgHIFU ablation of bone results in progressive bone remodeling. New bone formation appears to be related to the use of higher energies. MRI and CT are suitable noninvasive techniques to monitor bone remodeling following MRgHIFU.

References:

1. Gianfelice D, Gupta C, Kucharczyk W, Bret P, Havill D, Clemons M. Palliative treatment of painful bone metastases with MR imaging--guided focused ultrasound. *Radiology* 2008;249(1):355-363.
2. Kopelman D, Inbar Y, Hanannel A, Pfeffer RM, Dogadkin O, Freundlich D, Liberman B, Catane R. Magnetic resonance guided focused ultrasound surgery. Ablation of soft tissue at bone-muscle interface in a porcine model. *Eur J Clin Invest* 2008;38(4):268-275.