

Common and Uncommon Mimics of Primary Liver Cancers: MRI Characteristics, Differentiating Features and Histopathological Correlation

Pardeep Mittal¹, Courtney C Moreno¹, Juan C Camacho¹, Brian Quigley², Kiran K Maddu¹, Nima Kokabi¹, William Small¹, and Bobby Kalb³

¹Radiology and Imaging Sciences, Emory Uni School of Medicine, Atlanta, Georgia, United States, ²Pathology, Emory Uni School of Medicine, Atlanta, Georgia, United States, ³Diagnostic Radiology, University of Arizona, Tucson, Arizona, United States

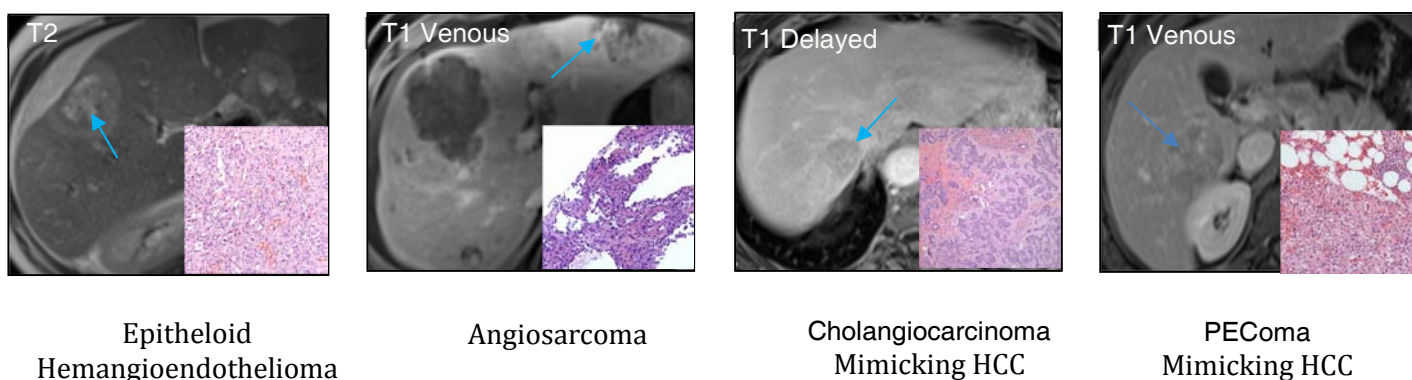
Purpose:

- To demonstrate MRI characteristics of primary liver cancers in chronic liver disease (CLD) and non CLD and differentiating features.
- To describe common and uncommon mimics of primary liver cancers and overlapping features.
- To describe histopathological features of primary liver malignancies and their mimics.
- Also demonstrate characteristics of primary liver tumors in pediatric population.

Methods: The presentation includes review of MR examinations of patients for characterization of liver lesions in CLD and non CLD using dedicated MRI protocol with and without contrast medium. MRI findings were correlated with histopathological findings.

Discussion: Liver is an important organ from oncologic perspective. Primary liver cancers are more common in presence of CLD than non CLD such as cirrhosis, hemochromatosis etc. Primary liver tumors arise from different components of liver such as hepatocytes, bile duct epithelium, neuroendocrine cells and mesenchymal cells. Hence we will discuss imaging and histopathological features of hepatocellular carcinoma, cholangiocarcinoma, cholangiocellular carcinoma, epithelioid hemangioendothelioma, angiosarcoma, lymphoma etc. and their common and uncommon mimics such as FNH, neuroendocrine tumors, lymphoepithelioma, extramedullary hematopoiesis, inflammatory tumors, sclerosing hemangioma. Patient's age is also an important discriminating factor because some tumors occur in pediatric age group such as hepatoblastoma, mesenchymal hamartoma, infantile hemangioendothelioma etc.

Conclusions: MRI has become the most important diagnostic tool over other imaging modalities due to its excellent soft tissue contrast and multi planar capabilities which assist in diagnostic accuracy as well as promoting successful management and follow up of such lesions and more over no ionizing radiation involved.



References:

1. Buetow, P.C., et al., Malignant vascular tumors of the liver: radiologic-pathologic correlation. Radiographics, 1994. 14(1): p. 153-166.
2. Mattison, G.R., et al., MR imaging of hepatic focal nodular hyperplasia: characterization and distinction from primary malignant hepatic tumors. American Journal of Roentgenology, 1987. 148(4): p. 711-715.
3. Powers, C., et al., Primary liver neoplasms: MR imaging with pathologic correlation. Radiographics, 1994. 14(3): p. 459-482.