

Comparison of Fetal Blood Flow Measured at 1.5T and 3.0T Using Phase Contrast MR and Metric Optimized Gating: Preliminary Results

Christopher K Macgowan¹, Beverly Tsai Goodman², Mashael Alrujaib³, and Mike Seed⁴

¹Departments of Medical Biophysics and Medical Imaging, Hospital for Sick Children / University of Toronto, Toronto, Ontario, Canada, ²Department of Paediatric Cardiology, Bristol Children's Hospital / University of Bristol, United Kingdom, ³Department of Paediatrics and Division of Cardiology, Hospital for Sick Children / University of Toronto, Ontario, Canada, ⁴Department of Paediatrics and Division of Cardiology, Hospital for Sick Children / University of Toronto, Toronto, Ontario, Canada

Introduction: Quantification of human fetal blood flow using phase contrast (PC) MR with metric optimized gating (MOG) has recently been demonstrated in studies of normal pregnancies and fetal left-sided congenital heart disease (1-3). These studies were performed at a field strength of 1.5T; however, there is growing interest in fetal imaging at higher field strengths to improve SNR. The goal of this pilot study was to evaluate the agreement between fetal flows measured at 1.5T and 3.0T, using PC MR with MOG.

Materials and Methods: All studies were approved by our institutional research ethics board. Fetal flows were quantified in 5 subjects (gestational ages: 35–38 weeks) with the following clinical statuses: two normal pregnancies; one fetus with a family history of Noonan syndrome; and two congenital heart disease (CHD) patients with disproportionate ventricular sizes, smaller left ventricles and aortic arch hypoplasia.

Data were obtained at both 1.5T and 3.0T (Siemens Avanto and TRIO, respectively) using a previously reported protocol [2]. Scans were performed on the same day except for one case for which the second scan occurred one week later. To avoid procedural bias, scanner order was alternated between subjects. For each examination, fetal flows were acquired in the main pulmonary artery, ascending aorta, superior vena cava, ductus arteriosus, descending aorta, umbilical vein, and left and right pulmonary arteries to give pulmonary blood flow (i.e. 7 flows per fetus). Relevant imaging parameters were: spatial resolution = 1.3x1.3 mm², temporal resolution = 51.5 ms, venc = vessel dependent (50–150 cm/s), and scan time = 27 seconds. A 3D SSFP acquisition was also performed at each field strength to estimate fetal mass for flow normalization [2].

After MOG reconstruction of the PC MR data, blood flow (ml/min) was quantified by an experienced cardiologist using QFlow (Medis, NL). For body mass estimation, fetal volume was measured from the 3D SSFP data using Mimics (Materialise Group, Belgium) [2]. Reproducibility of flow measurements at the two field strengths was assessed by Pearson correlation coefficient, linear regression and Bland-Altman analysis.

Results and Discussion: Flows were obtained in 31 of 35 targets. In one 3T examination (family history of Noonan syndrome), persistent fetal motion corrupted data from the ductus arteriosus, umbilical vein, and the pulmonary arteries. Figure 1a presents a correlation plot from the remaining 31 flow comparisons, showing strong agreement between corresponding measurements ($R^2 = 0.78$). Linear regression revealed a potential bias at low and high flows, although the number of measurements in these regimes was low. Figure 1b is a Bland-Altman plot of the same data, with a bias and 95% confidence interval (C.I.) of -1 ml/min/kg and 71 ml/min/kg, respectively. These collective metrics for between-visit reproducibility are comparable to studies performed in adults, demonstrating the reliability of the method [4,5].

Limitations of this pilot study are as follows. First, changes in the physiological state of the fetus (and mother) between scans are an inevitable confound. Second, in one fetus the scans were repeated one week apart rather than on the same day, which could further reduce overall agreement. To account for changes in flow associated with maturation, flows were normalized by fetal mass. Last, background phase correction was not applied to these interim results. Despite these limitations, flows obtained at 1.5T and 3.0T were in good agreement.

Conclusion: Fetal flows measured using PC MR with MOG at 1.5T and 3.0T showed high correlation and negligible global bias. These early findings suggest that PC MR may be included in fetal protocols at 3.0T.

References: [1] Jansz, *Magn Reson Med*. 2010, 64:1304; [2] Seed, *J Cardiovas Magn Reson*. 2012, 26:14; [3] Al Nafisi, *J Cardiovas Magn Reson*. 2013, 15:65; [4] Spilt, *J Magn Reson Imaging*. 2002, 16:1; [5] Macgowan, *J Magn Reson Imaging*. 2013, doi:10.1002/jmri.24388

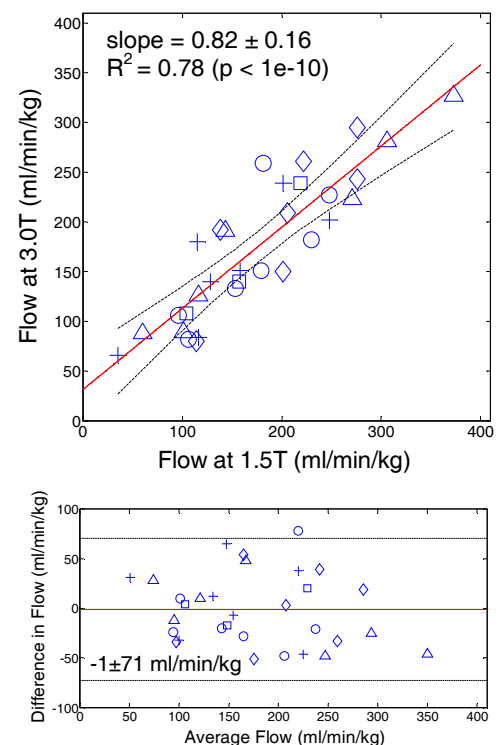


Figure 1: (a) Comparison of fetal flows (5 subjects) measured at 3.0T versus 1.5T using PC MRI with MOG. Symbols: Diamond & Plus = normal pregnancy; Square = family history of Noonan syndrome; Circle & Triangle = CHD; Red line = linear regression; Dashed lines = 95% C.I. (b) Bland-Altman analysis of data from (a). Red line = mean; Dashed = 95% C.I.