

More accurate estimation in prostate volume achieved by optimized single slab 3D SPACE compared with 2D-TSE: A quantitative study based on the radical prostatectomy specimens.

Souichirou Tateishi¹, Masato Uchikochi², Shohei Miyazaki¹, Hitoshi Matsui¹, Takashi Horinouchi¹, Yasuhiko Tomita³, Kazuo Nishimura⁴, and Katsuyuki Nakanishi¹

¹Radiology, Osaka Medical Center for Cancer and Cardiovascular Diseases, Osaka, Osaka, Japan, ²SIEMENS JAPAN K.K., Tokyo, Japan, ³Pathology, Osaka Medical Center for Cancer and Cardiovascular Diseases, Osaka, Japan, ⁴Urology, Osaka Medical Center for Cancer and Cardiovascular Diseases, Osaka, Japan

Introduction

More accurate noninvasive estimation of prostate volume is important in therapeutic trials for prostate cancer. Superior contrast resolution of MRI leads more accurate than transrectal ultrasound (TRUS) and CT for prostate volume estimation. The conventional sequence used for calculations of prostate volume has been 2D-TSE T2WI. A recently evolved 3D-TSE T2WI sequence termed SPACE (Sampling Perfection with Application Optimized Contrasts using different Flip Angle Evolutions, Siemens) provides a high spatial resolution and isotropic volume image compared with the conventional 2D-TSE sequences. These improvements expect to provide more accuracy in prostate volume estimation. The purpose of our study is to evaluate the accuracy of prostate volume measurement using SPACE compared to the conventional 2D-TSE.

Materials and Methods

This retrospective study was approved by the institutional review board, and informed consent was obtained. Prostate images were acquired on 40 patients (mean age; 64.7 ± 6.48 , with prostate cancer) using 3.0T scanner (MAGNETOM Trio, A Tim System, Siemen, Erlangen, Germany) with the combined phased-array coil. Both sequences parameters were as follows: 1) 3D-T2WI SPACE; TR/TE=2500/240msec, voxel size=1.0x1.0x1.0mm (matrix size=320x320, slice thickness=1mm, phase resolution=100%, slice resolution=70%, FOV=320mm, Flip angle mode=T2 variable), 2) 2D-TSE T2WI; TR/TE=4000/92msec, voxel size=0.8x0.6x4.0mm (matrix size=384x288, slice thickness=4mm, slice gap=0%, FOV=220mm). Volume calculations of the whole prostate were performed on a workstation (Zio Station, Ziosoft, Inc.). A radiological technologist with 10 years of experience in prostate MRI reviewed computer outlines of the prostate. In case of 2D-TSE, incorrectness in contouring especially at the base and the apex of the prostate was concerned. Therefore, the averages of volume measured by 2planes (axial, sagittal) were adapted. Reference standard of prostate volume was obtained from pathology report as a gold standard, which were noted at our institution. Statistical Analysis was the Pearson correlation coefficient and the relative error was calculated between the estimated prostate volume and the reference standard of prostate volume.

Results

For the reference average total prostate volume was $50.29 \pm 22.7\text{cm}^3$ (range, 25.0-120.0 cm^3). The estimated volumes were as follow: 1) SPACE $48.41 \pm 25.6\text{cm}^3$ (range, 16.5-128.6 cm^3 , 2) 2D-TSE $49.26 \pm 29.4\text{cm}^3$ (range, 16.9-130.7 cm^3). The estimated volume using SPACE showed a higher correlation than using 2D-TSE with reference standard of prostate volume (SPACE; $r=0.98$, 2D-TSE; $r=0.96$). The calculated relative error for SPACE was 0.12 ± 0.13 while that for 2D-TSE was 0.19 ± 0.15 ($p<0.01$).

Discussion

The present study demonstrated that SPACE was more linearly related to the radical prostatectomy volume and less relative error than 2D-TSE. These results were caused by artifact such as partial volume and chemical shift. SPACE enabled the acquisition of both isotropic volume image and less chemical shift image compared with 2D-TSE. Especially, isotropic image enabled to contour volume with 3planes.

Conclusion

SPACE should be the preferred method for measuring prostate volume.

References

1) Karademir I, Shen D, et al. Prostate volumes derived from MRI and volume-adjusted serum prostate-specific antigen: correlation with Gleason score of prostate cancer. AJR. 2013 Nov; 201(5)

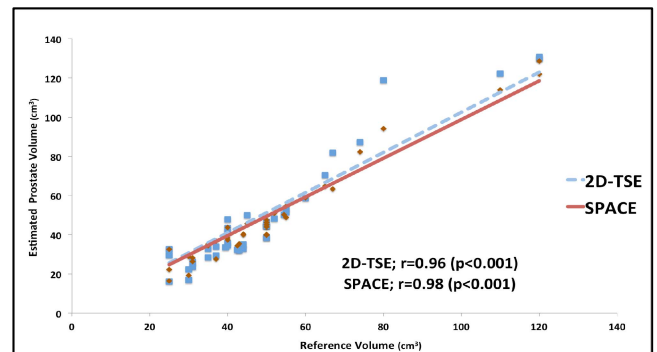


Fig.1 Correlation between estimated volume from MRI examinations and reference volume based on specimen weight.

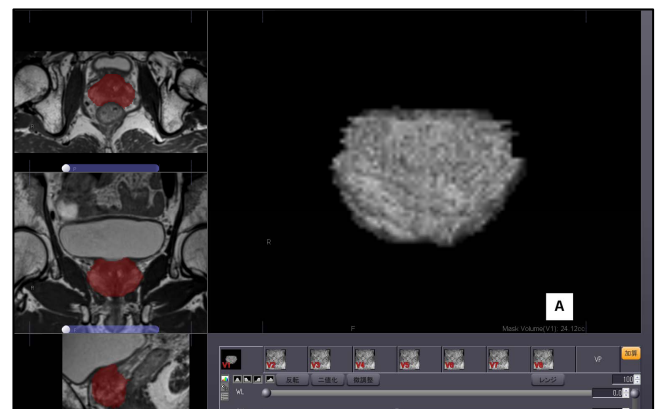


Fig.2 Screen-capture image from Zio Station shows that 3D prostate volume was acquired with 3planes (axial, coronal, sagittal). By use of SPACE, prostate volume was measured with more accuracy.