

## ASL and BOLD MRI Measurements in Human Kidneys

Jon Thacker<sup>1</sup>, Huan Tan<sup>2</sup>, Lu-Ping Li<sup>3,4</sup>, Wei Li<sup>3</sup>, Stuart Sprague<sup>4,5</sup>, Orly Kohn<sup>6</sup>, Ivana Lazich<sup>6</sup>, and Pottumarthi V Prasad<sup>3,4</sup>

<sup>1</sup>Northwestern University, Evanston, IL, United States, <sup>2</sup>Department of Surgery, University of Chicago, IL, United States, <sup>3</sup>Department of Radiology, Northshore University HealthSystem, IL, United States, <sup>4</sup>The University of Chicago Pritzker School of Medicine, IL, United States, <sup>5</sup>Division of Nephrology, Northshore University HealthSystem, IL, United States, <sup>6</sup>Section of Nephrology, The University of Chicago Pritzker School of Medicine, IL, United States

**BACKGROUND:** Renal hypoxia and ischemia are considered key contributors to progression in chronic kidney disease (CKD) [1]. Unlike most organs, kidneys do not follow the normal relationship of increased oxygenation with increased blood flow [2]. An increase in renal blood flow results in increased glomerular filtration rate (GFR) and hence increased sodium delivery to medullary thick ascending limbs (mTAL). This in turn leads to increased oxygen demand to support sodium reabsorption along mTAL [2]. Hence, measurement of oxygenation independent of perfusion is desired in the kidney.

With the revelation of nephrogenic systemic fibrosis (NSF) a few years back, gadolinium based contrast media are contraindicated in subjects with compromised renal function such as those with CKD. This has led to increased interest in endogenous contrast mechanisms in the evaluation of kidneys in patients with CKD. Blood oxygenation level dependent (BOLD) MRI has gained acceptance in the evaluation of intra-renal oxygenation and arterial spin labeling (ASL) methods are showing promise in the evaluation of renal cortical perfusion [3].

In this study, we tested whether renal oxygenation is correlated with perfusion by combining BOLD based renal oxygenation with ASL perfusion measurements.

**METHODS:** BOLD MRI and ASL measurements were made in a group of 21 subjects with 13 healthy controls and 8 patients with stage 3 CKD. Studies were performed on a 3T Siemens scanner with a body array coil. The protocol consisted of initial measurements being made using the BOLD and ASL sequences. Following baseline measurements, an intravenous injection of furosemide (Sigma Chemical Co., St. Louis, MO; 10mg/kg bw) was administered and BOLD MRI measurements were repeated.

BOLD measurements were performed using a multi-echo gradient recalled echo (mGRE) sequence with one slice per breath-hold for a total of 5 axial slices. Eight echo times were acquired starting at 3.09ms and incremented by 3.92ms. The remaining imaging parameters were as follows: TR=62ms, FA=30°, BW=260Hz/px, slice=5mm, matrix=256x192 and FOV 36-42cm with 80% phase FOV. R2\* maps were made by performing a nonlinear least squares fit across the echo times on a pixel basis. Regions of interest were defined in the cortex and medulla on each slice and the mean of each region of interest was evaluated. Finally, the mean of each region across all slices and both kidneys was calculated to give a single value for the cortex and medulla per subject. This was performed for both pre- and post-furosemide acquisitions. The relative change in R2\* ( $\Delta R2^*$ ) was defined as (pre - post) / pre.

Perfusion images were acquired with a retrospective navigator gated ASL sequence [4]. An inversion time of 1.5s for healthy volunteers and 2s for the CKD patients was used. An oblique coronal imaging plane was matched to the long axis of both kidneys. The rest of imaging parameters were as follows: FA=60°, echo spacing=4, TE=2.02ms, TR=3s, BW=651Hz/Pixel, matrix=128x128, FOV=36-40cm, slice thickness=8mm, and GRAPPA factor = 2.

Intragroup comparisons were made to assess pre and post-furosemide changes with the Wilcoxon signed rank test. Intergroup comparisons for determining any relationship between parameters in control and CKD groups was performed using the Mann-Whitney-U test. Correlations were assessed using a linear regression model and Pearson's r test. All tests were performed using 0.05 significance level.

**RESULTS:** No correlation was observed ( $p > 0.05$ ;  $|r| < 0.39$ ) between R2\* and ASL cortical perfusion values in either cortex or medulla and pre- or post- furosemide in either healthy or CKD groups. Cortical perfusion was found to be significantly higher in healthy subjects compared to CKD patients ( $p < 0.05$ ;  $z=16.0$ ). Figure 1 shows a box plot for cortical ASL values in the two groups. Figure 2 shows box plots for R2\* values in each of the regions and groups. Figure 3 shows box plots for  $\Delta R2^*$  in both regions and groups. There was a significant difference in  $\Delta R2^*$  ( $p < 0.05$ ;  $z=22.0$ ) between healthy and CKD in medulla but not in the cortex. This is expected since furosemide's action is localized to the medulla.

**CONCLUSION:** As expected, there was no correlation between R2\* and ASL measurements in any of the cases. This supports our hypothesis that renal oxygenation is independent of perfusion and the two should be assessed separately. A significant difference was observed between cortical perfusion and medullary  $\Delta R2^*$  values in control and CKD. Each of these measurements provides independent information with regards to renal health in CKD subjects.

**REFERENCES:** [1] Fine et. al. *Kidney Int Suppl.* 1998; 65: S74-8. [2] Heyman et. al. *Am J Nephrol.* 2008;28(6):998-1006. [3] Zhang JL, *Kidney Int.* 2013 PMID: 24067433. [4] Tan et. al. *MRM* 2013 PMID: 23447145.

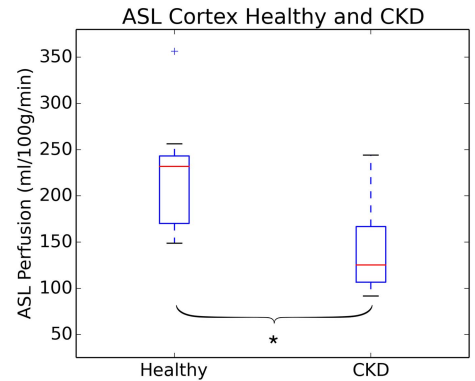


Figure 1: Cortical ASL in Healthy and CKD. \* indicates a significant difference ( $p < 0.05$ ) between groups.

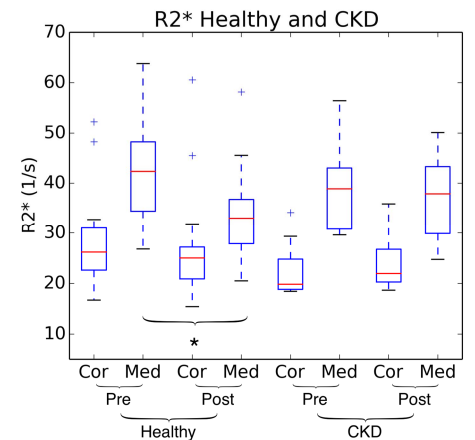


Figure 2: R2\* in Healthy and CKD. \* indicates a significant difference ( $p < 0.05$ ) between groups.

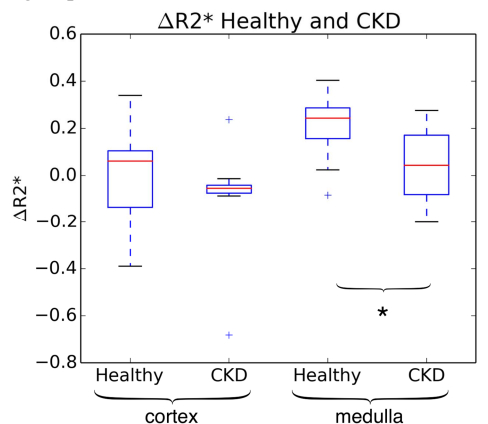


Figure 3:  $\Delta R2^*$  in Healthy and CKD. \* indicates a significant difference ( $p < 0.05$ ) between groups.