

# Ultra-short Echo Time 3D Radial Retrospective self-gated navigator for lung motion correction

Konstantinos G. Zeimpekis<sup>1,2</sup>, Gaspar Delso<sup>3</sup>, Florian Wiesinger<sup>4</sup>, Patrick Veit-Haibach<sup>5</sup>, and Gustav von Schulthess<sup>5</sup>

<sup>1</sup>University Hospital, Zurich, Zurich, Switzerland, <sup>2</sup>Information Technology and Electrical Engineering, ETHZ, Zurich, Zurich, Switzerland, <sup>3</sup>Global MR Applications & Workflow, GE Healthcare, Waukesha, WI, United States, <sup>4</sup>GE Global Research, Munich, Germany, <sup>5</sup>University Hospital, Zurich, Switzerland

**TARGET AUDIENCE:** Lung - Body MRI, physicists

**INTRODUCTION:** MR lung imaging is challenging due to lung inherent low proton density, very short T2\*, large susceptibility effects and respiratory motion that can introduce artefacts and degrade image quality. Standard methods to avoid respiratory motion artefacts include external devices like respiration belts [1]. Ultra-short Time Echo (UTE) sequences can be used in free-breathing acquisitions leading to satisfactory image quality. Image quality can be further improved if a self-gating navigator is applied, taking advantage of the DC signal inherent oversampling in 3D Radial trajectory sequences [2-4]. Projected Radial (PR) imaging presents robustness to motion. Other advantages involve not using extra rf pulses for determining navigators and external devices [5]. We propose a retrospective respiratory gating implementation based on the detection of the respiration profile by DC signal and gating of the end-expiration phase.

**METHODS:** Data from healthy volunteer subjects with normal breathing cycle were acquired on a GE Discovery MR750w 3T scanner. The acquisition time per scan was 5.52 minutes with a 3D PR, fast spoiled gradient echo pulse sequence: TR=7.6 ms, TE=0.01 ms, FA=6°, FOV=30\*30\*26.5 cm<sup>3</sup>, isotropic resolution=1.6 mm and 160 slices. The central k-space point, containing the DC signal from one of the coil elements that are near to the diaphragm and can record lung motion was chosen for the navigator extraction. Four identical scans were acquired and the DC navigator was extracted from each of them. After, superimposing and rescaling all 4 navigators, the interleaves corresponding to end-expiration phase were selected for all coils. The final data for reconstruction had the size of one acquisition with a mixture of interleaves from all scans that meet the condition of the highest values of the end-expiration phase. Reconstruction was done offline using MATLAB (The Mathworks, Natick, USA).

**RESULTS:** Figure 1a shows the extraction of the best DC signal from the coil that is sensitive near the diaphragm. DC detects the respiration motion with higher amplitude representing the end-expiration phase. Figure 1b shows the four DC signals with the DC navigator selecting only maximum value interleaves that correspond to end-expiration. 81% of the interleaves used corresponded to end-expiration phase. Figure 2 depicts coronal planes before and after gating. The artifacts and blurring effect are reduced in both Maximum Intensity Projection and single slice planes. Deep bronchial branches, pneumonic arteries and vessels are imaged with improved contrast. Structures near the diaphragm are better defined, avoiding motion blurring.

**CONCLUSION:** The respiratory signal can be detected from the acquisition of central k space and used for retrospective self-gating of 3D-UTE sequences. The implementation of a self-gated acquisition leads to better resolution and overall image quality, correcting for lung motion and potentially enabling the imaging of lung parenchyma. Future plans involve 3D Cones sequence self-gating to shorten the scan time and the implementation of prospective self-gating.

## REFERENCES:

- [1] Arnold et al., MRM 58:1092-1098 (2007)
- [2] Crowe et al., MRM 52:782-788 (2004)
- [3] Buehrer et al., MRM 60:683-690 (2008)
- [4] Brau et al., MRM 55:263-270 (2006)
- [5] Weick et al., JMRI 37:727-732 (2013)

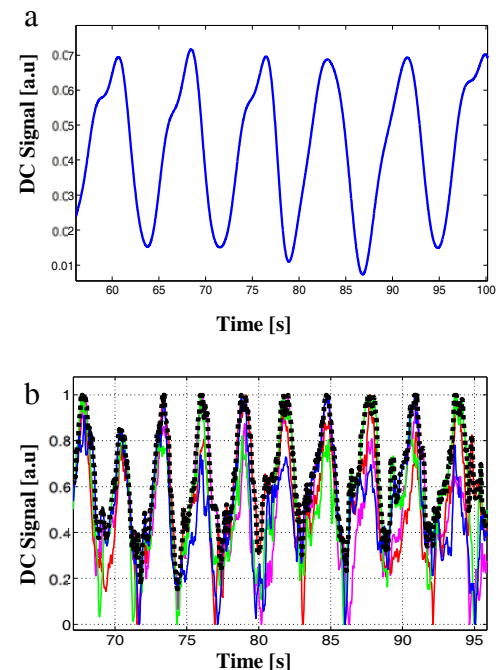


Figure 1. **a.** Respiration pattern detected by DC signal, **b.** Superimposed DC navigators from the 4 acquisitions with final selected DC self-navigator (black dashed line)

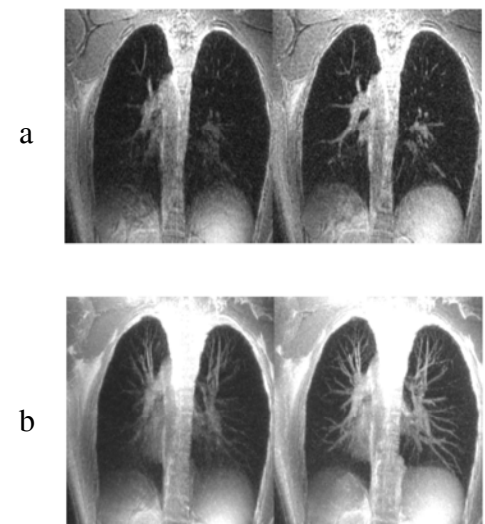


Figure 2. **a.** Ungated (left) and self-gated (right) coronal images, **b.** Maximum Intensity Projection of ungated (left) and self-gated coronal images over 32 mm thin slab