

Multiparametric functional 1H-lung MRI using a free-breathing 3D Twisted Projection Imaging Sequence

Kathrin R Hemberger¹, Daniel Haddad¹, Peter M Jakob^{1,2}, and Felix A Breuer¹

¹Magnetic Resonance Center Bavaria, Wuerzburg, Bavaria, Germany, ²Department of Experimental Physics 5, Wuerzburg, Germany

Introduction: Oxygen-enhanced MR can evaluate lung function via changes in T2* [1] and T1 [2]. While changes in T2* are directly related to ventilation, changes in T1 are also influenced by perfusion and diffusion and can be described by the oxygen transfer function (OTF). In order to provide several functional parameters in one measurement in 3D we employ a modified T1-weighted Twisted Projection Imaging (TPI) [3] sequence with different TEs. With retrospective DC gating the sequence allows for 1) quantitative assessment of T2* 2) T1-weighted imaging and 3) relative spin density (SD) mapping in arbitrary breathing states e.g. inspiration and expiration.

Materials and Method: The sequence was implemented on a clinical 1.5T scanner. In TPI each k-space trajectory starts as a center-out radial line and then twists to maintain a constant sampling density with a fixed gradient readout and therefore yields high acquisition efficiency. To achieve a flexible sampling in time we rotate this trajectory for every TR and employ a 2D quasi random sampling scheme. For subsequent readouts the TE was changed according to TE = [0.07/0.6/1.0/2.0/3.0ms]. Data were acquired during free breathing at room air (RA) and 100% O2 using following parameters: FoV=500x500x500mm³; TR=8ms; flip angle=10°. TA=21:06min. Image reconstruction was done offline using the NUFFT algorithm [4]. The center k-space signal serves as gating signal for retrospective gating [5]. The measured signal was mono-exponentially fitted versus TE to generate 3D T2* maps and SD maps reflecting also T1 weighting. Regions of interest (ROI) were drawn in the whole right and whole left lung in one coronal slice.

Results: The expected changes in T2* were obtained and are listed in Table 1. Exemplary T2* maps are displayed in Figure 1. Figure 2 shows T1-weighted images from the same data set for the different breathing gases and the corresponding difference image. The signal change due to T1-shortening was on the order of 10%. Figure 3 shows relative SD maps for expiration and inspiration. The changes obtained in the relative SD were on the order of 38%.

	T2*(ms), Left/right inspiration	T2*(ms), Left/right expiration
Room air	2.0/1.8	2.0/1.9
Pure oxygen	1.8/1.6	1.8/1.7
Relative change (%)	11/10	11/10

Tab. 1. Calculated T2* values.

Conclusion: Using two 3D-TPI measurements only at room air and 100% O2 we were able to assess simultaneously

- 1) Absolute T2* changes after breathing oxygen (10%) → ventilation
- 2) Relative signal changes in T1 after breathing oxygen (10%) → oxygen transfer
- 3) Relative SD changes in expiration-inspiration (39%) → ventilation.

The availability of all these parameters in 3D may improve diagnostic accuracy in several lung diseases.

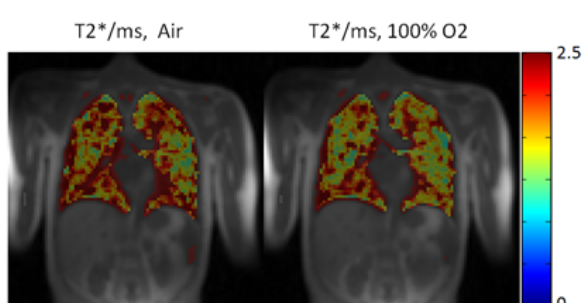


Fig. 1. Calculated T2* maps when breathing room air and when breathing pure oxygen (in expiration).

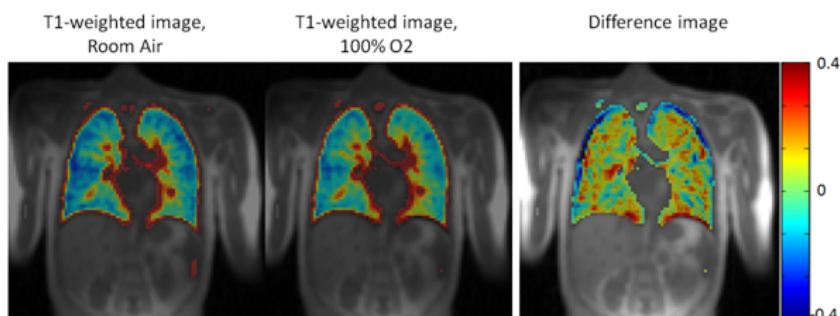


Fig. 2. T1-weighted imaging while breathing room air and pure oxygen and the corresponding difference image, which demonstrates the oxygen-transfer into the blood.

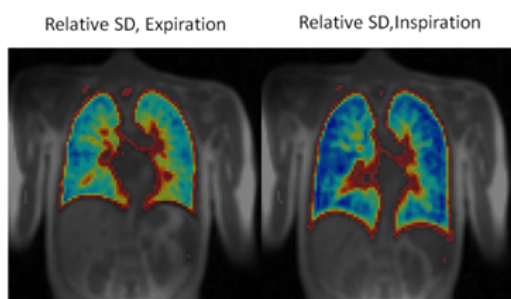


Fig. 3. Calculated expiratory and inspiratory relative spin density maps when breathing pure oxygen.

- References:** [1] Edelmann et al., Nat Med 1996; 2: 1236-1239.
 [2] Pracht et al., MRM 2005; 53: 1193-1196.
 [3] Boada et al., MRM 1997; 37: 706-71.
 [4] Fessler, JMR 2007; 188: 191-195
 [5] Brau et al., MRM 2006; 55:263-270.

Acknowledgements: The authors like to thank Siemens Healthcare for technical support.