

# Hyperintensity in the Cerebral Venous Systems on 3D TOF MRA: Better Understanding of the Mechanism Using Dynamic Head and Neck MRA

Eung Yeop Kim<sup>1</sup> and Jun-Young Chung<sup>2,3</sup>

<sup>1</sup>Radiology, Gachon University Gil Medical Center, Incheon, Korea, <sup>2</sup>Biomedical Engineering, College of Health Sciences, Gachon University, Seongnam, Korea, <sup>3</sup>Neuroscience Research Institute, Gachon University, Incheon, Korea

## Background

The cerebral venous sinuses may normally show hyperintensity on cerebral time-of-flight (TOF) MRA, which oftentimes mimics pathologic conditions such as arteriovenous fistula. It has been reported that it is more common on the left because of physiologic compression of the left brachiocephalic vein (BCV), which may ultimately cause reverse flow.<sup>1</sup> However, hyperintense veins are also seen on the right, which is not easy to be explained. In previous studies, small subjects have only been evaluated for their extracranial venous systems. We hypothesized that the source images of contrast-enhanced dynamic MRA may help comprehensively evaluate them, and reciprocal relationship between the inferior petrosal sinus (IPS) and other veins including the anterior condylar and lateral condylar veins (ACV and LCV) could determine the preferential direction of reverse flow.

## Purpose

By using the source images of contrast-enhanced dynamic MRA, we sought to determine the factors attributable to reverse flow into the cerebral venous sinus, which shows hyperintensity on TOF MRA.

## Methods

We retrospectively assessed the venous systems of 55 patients (mean age, 59.8 years; M:F = 23:32) who underwent both cerebral 3D TOF MRA and 3D Time-resolved angiography With Interleaved Stochastic Trajectories (TWIST) MRA of the head and neck at 3T for various indications. Cerebral 3D TOF MRA was obtained with the following parameters: TR, 22 ms; TE, 3.74 ms; flip angle, 18°; FOV, 250 × 250 mm; matrix, 512 × 252; slabs, 5; thickness, 0.5 mm; acceleration factor, 2; acquisition time, 5 minutes 49 seconds. TWIST MRA was obtained after intravenous bolus administration of gadolinium contrast agent, followed by a 15-mL saline flush, via the right antecubital vein. Imaging parameters were the following: TR, 2.71 ms; TE, 0.99 ms; flip angle, 24°; rectangular FOV, 416 × 338 mm; matrix, 284 × 218; thickness, 1.2 mm; acceleration factor, 6; 30 phases; acquisition time, 1 minute 44 seconds. The presence of hyperintensity of the cerebral venous system was assessed in the inferior petrosal sinus (IPS), sigmoid sinus (SS), cavernous sinus (CS), and pterygoid emissary vein/plexus (PPV) on source images of 3D TOF MRA, and was determined when they showed higher signal intensity compared to the background one. Each side of the venous systems was separately evaluated. Extrinsic compression of the bilateral internal jugular veins (IJV) and BCVs was assessed on 3D TWIST MRA source images, and was considered when the veins showed a decrease of the luminal area more than 50% compared with the proximal one. The sizes of the IPS and others including ACV and LCV were visually compared on 3D TWIST MRA source images when they were optimally visualized (Fig).

## Results

Table summarizes the frequencies of hyperintensity in the IPS, SS, CS, and PPV, extrinsic compression of BCV and IJV, and the IPS larger or equal to other veins including ACV/LCV. Out of 28 patients who showed hyperintensity in the right IPS, 24 IPSs (85.7%) were larger or equal to the ipsilateral ACV/LCV ( $P < 0.0001$ ) irrespective of compression of the ipsilateral IJV. There was no effect of IJV compression or the size of IPS on the presence of hyperintensity in the SS, CS, and PPV on the right. Twenty-five left IPSs were significantly larger or equal to the ipsilateral ACV/LCV in 30 patients who demonstrated hyperintensity in the ipsilateral IPSs ( $P < 0.0001$ ). Compression of the left IJV was significantly associated with the presence of hyperintensity in the ipsilateral IPS and SS, ( $P = 0.026$  and  $0.014$ , respectively). There was no significant association between compression of left BCV and reverse flow in the ipsilateral IPS, SS, CS, or PPV ( $P > 0.05$ ) (Fig). Logistic regression analysis showed that the left IPS larger or equal to ipsilateral ACV/LCV was the only significant factor for demonstrating hyperintensity in the left IPS ( $P < 0.0001$ ; OR, 91.5 95% CI [10.0-834.0]). The presence of hyperintensity in the left IPS and SS was significantly related each other ( $P = 0.01$ ).

## Discussion

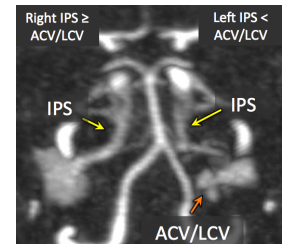
This study demonstrated that the relationship between the IPS and ACV/LCV is the only factor to determine the presence or absence of hyperintensity in the ipsilateral IPS. In contrast to the results of previous studies, left BCV was not attributable to the presence of hyperintensity in the ipsilateral venous system. While they did not assess all BCVs, we analyzed all BCVs as well as IJV and ACV/LCV using TWIST MRA source images. There has been no study with large population describing the frequency of extrinsic compression of the BCV. In addition, extrinsic compression of the right BCV is rare. Extrinsic compression of the IJV has recently been reported to be approximately 50% in adults,<sup>2</sup> which could be responsible for reverse flow rather than extrinsic compression of the BCV in particular on the right. On the left, extrinsic compression of left IJV may be ascribable to reverse flow in the ipsilateral IPS and SS. However, regression analysis showed that the size of the IPS was the only variable for the presence of reverse flow.

## Conclusion

The relative size of the IPS to the ipsilateral ACV/LCV is the only factor for visualization of hyperintensity in the IPS on both sides on cerebral TOF MRA. Extrinsic compression of left IJV may be attributable to the presence of hyperintensity in the left SS on cerebral TOF MRA.

## References

- Uchino et al., *Neuroradiology* 2007;49:211-215.
- Jayaraman, et al., *AJNR Am J Neuroradiol* 2012;33:1247-1250



	Reverse Flow Present on TOF MRA				Extrinsic Compression			IPS ≥ ACV/LCV
	IPS	SS	CS	PPV	BCV	IJV		
Right	28	18	5	4	0	35	26	
Left	30	28	15	9	23	39	27	
Bilateral	19	12	1	2	0	30	14	

