

# The expression of normal motor-related functional pattern using fMRI and PET in sporadic dystonia

Wataru Sako<sup>1</sup>, An Vo<sup>1</sup>, Aziz M Ulug<sup>1</sup>, and David Eidelberg<sup>1</sup>

<sup>1</sup>Center for Neurosciences, Feinstein Institute For Medical Research, Manhasset, NY, United States

**Target Audience** Neuroscientist, brain imager, dystonia researcher.

**Introduction** Normal motor-related pattern (NMRP) was originally identified in H<sub>2</sub><sup>15</sup>O PET study by multivariate analysis based on principal component analysis, and found to be more strongly expressed in patients with DYT1 dystonia than normal controls (NC)[1]. Studying a group of subjects with both fMRI and PET, we derived NMRP from each imaging modality. We then applied the NMRP patterns in a group of sporadic dystonia (SP) patients.

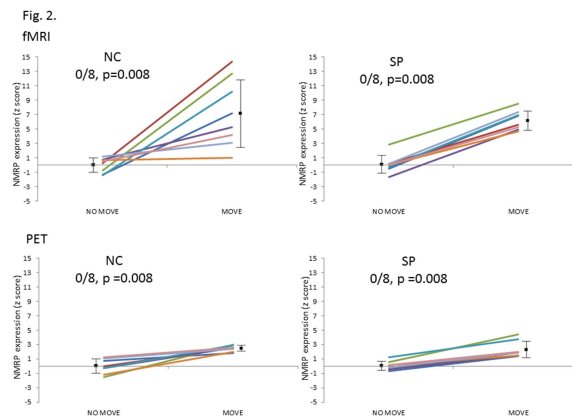
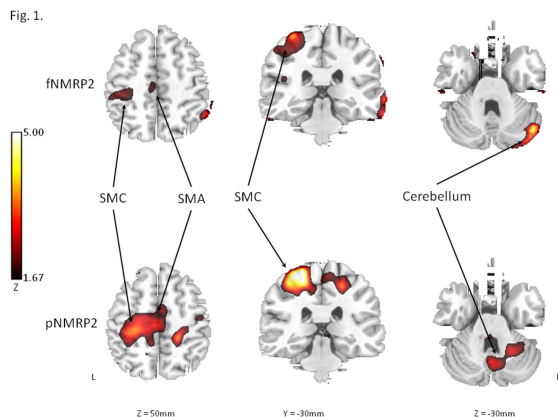
**Subjects and Methods** We studied 10 healthy controls (NC; 7 male, 3 female, 40.5 ± 10.5 yrs old) and 8 sporadic dystonia patients (SP; 5 male, 3 female, age 45.4 ± 15.0 yrs old) using fMRI and H<sub>2</sub><sup>15</sup>O PET. Eight of the ten NC and 8 SP underwent both imaging modalities. We used fMRI and H<sub>2</sub><sup>15</sup>O PET to assess brain activation during each condition with and without movement. For movement condition, subjects moved their right hand as a cursor moved from a central starting point to one of eight radially arrayed targets. In contrast, the condition without movement consisted of just watching one of the targets lighten. Images were acquired in a 3T GE whole-body MR scanner with an eight-channel head coil. The fMRI protocol included FOV of 240 mm, 40 slices with 3 mm thickness, imaging matrix of 64 × 64, flip angle 77 degrees, TR of 2 sec, TE of 27.2 ms and scan time 240 sec. A high resolution T1-weighted structural image was also acquired for each subject with resolution of 0.9 × 0.9 × 1 mm<sup>3</sup>. The T1-weighted structural image protocol included FOV of 240 mm, 176 slices with 1 mm thickness, imaging matrix of 256 × 256, flip angle 8 degrees, TR of 7.6 ms, TE of 2.9 ms, TI of 650ms. PET imaging was performed in 3D mode using a GE Advance tomograph. The 18-ring bismuth germinate scanner provided 35 image planes with an axial field of view of 14.5 cm and an intrinsic resolution of 4.2 mm (FWHM) in all directions. Image pre-processing and first-level analyses were performed using FEAT in FMRIB software [2]. The activation map was created for each individual according to general linear model (GLM) in first-level analysis. Second-level analysis was conducted through the results of first-level analysis by ordinal trends canonical variates analysis (OrT/CVA) [3] and an fMRI derived NMRP pattern fNMRP and a PET derived NMRP pattern pNMRP were obtained.

**Results** The fNMRP was derived from activation maps of 10 NC using OrT/CVA. Likewise, pNMRP was derived from H<sub>2</sub><sup>15</sup>O PET images of 8 NC. Both NMRPs were consistently more expressed during movement task in comparison to sensory task (permutation test,  $p < 0.05$ ). The activated regions in fNMRP were similar to pNMRP, including sensorimotor cortex (SMC), supplementary motor area (SMA) and cerebellum (Fig. 1). The same result was observed if each NMRP was applied to the eight of the ten NC and 8 SP who underwent both fMRI and H<sub>2</sub><sup>15</sup>O PET (Fig. 2). The effects of condition and group were analyzed using two-way repeated measures ANOVA with within-subject's factor of condition, and between-subject's factor of group in fMRI and PET separately. There were no significant interaction effects between these factors (fMRI:  $F(1,14)=0.319$ ,  $P=0.581$ ; PET:  $F(1,14)=0.254$ ,  $P=0.622$ ).

**Discussion/Conclusions** We identified NMRP in fMRI and PET with similar activated regions. No significant difference of NMRP expression during task was observed between patient and control groups in fMRI or PET. Our findings suggested that the over-expression of NMRP in dystonia may be limited to DYT1 dystonia patients.

**Acknowledgments** This study was supported in part by a grant R01 NS072514 from NIH-NINDS.

**References** 1) Carbon M. et al., Brain 133(Pt3), 690-700 (2010). 2) <http://www.fmrib.ox.ac.uk/fs/>. 3) Habeck C, et al., Neural Comput 17, 1602-1645 (2005).



**Fig. 1.** Normal motor-related pattern (NMRP) topographies derived from fMRI and PET images. Both modalities detected significantly higher expression of NMRP during movement task than non-movement task. Permutation test was performed for statistical analysis and  $p < 0.05$  was considered as significant. Both

patterns were characterized by sensorimotor cortex (SMC), supplementary motor area (SMA) and cerebellum. MNI coordinates are shown.

**Fig. 2.** Normal motor-related pattern (NMRP) expression in the subjects who underwent both fMRI and PET. All expression scores were transformed to z value using each "NO MOVE" condition of 8 normal controls (NC) who underwent fMRI and PET both as a reference. Top: NMRP expression in fMRI. Bottom: NMRP expression in PET. Both modalities can detect significantly higher expression of NMRP during movement task than non-movement task in both NC and sporadic dystonia patients (SP). The line with same color indicates the same subject in each group. Group means and standard deviations were shown. Binominal test was applied for statistical analysis.