

# Blood-Brain Barrier Stabilization Effects of Agmatine Assessed by Dynamic Contrast-Enhanced MRI in a Rat Model of Transient Cerebral Ischemia

Sung Soo Ahn<sup>1</sup>, Se Hoon Kim<sup>2</sup>, Jong Eun Lee<sup>3</sup>, Kook Jin Ahn<sup>4</sup>, Dong Joon Kim<sup>1</sup>, Hyun Seok Choi<sup>4</sup>, Seung-Koo Lee<sup>1</sup>, and Yoon Seong Choi<sup>1</sup>

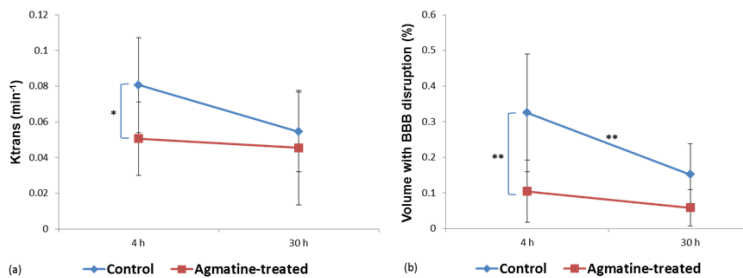
<sup>1</sup>Radiology, Yonsei University College of Medicine, Seoul, Korea, <sup>2</sup>Pathology, Yonsei University College of Medicine, Seoul, Korea, <sup>3</sup>Anatomy, Yonsei University College of Medicine, Seoul, Korea, <sup>4</sup>Radiology, The Catholic University College of Medicine, Seoul, Korea

**Introduction:** Blood-brain barrier (BBB) disruption after acute ischemic stroke and subsequent permeability increase may be enhanced by reperfusion.<sup>1</sup> Agmatine has been reported to attenuate BBB disruption.<sup>2</sup> Therefore, the aim of this study was to evaluate BBB stabilization effect of agmatine in a rat model of transient cerebral ischemia using permeability (dynamic contrast-enhanced, DCE) MRI at early stages, and to demonstrate the feasibility of DCE-MRI for the investigation of new therapies.

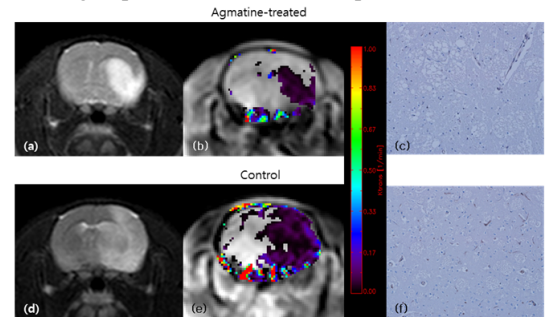
**Methods:** Thirty male Sprague-Dawley rats were subjected to transient middle cerebral artery occlusion for 90 min. Immediately after reperfusion, agmatine (100 mg/kg) was injected intraperitoneally in the agmatine-treated group (n=15) and normal saline in the control group. MRI was performed at 4 hours and 30 hours after reperfusion. For quantitative analysis, regions of interest were defined within the infarct area and volume transfer constant (K<sub>trans</sub>), rate transfer coefficient (K<sub>ep</sub>), and volume fraction of extravascular extracellular space (V<sub>e</sub>) values were obtained. The numbers of factor VIII positive cells were counted after immunohistochemical staining. Infarct volume, infarct growth, quantitative imaging parameters, and numbers of factor VIII positive cells were compared between the control and the agmatine-treated groups.

**Results:** Agmatine reduced infarct volume (36.1±10.8% vs. 54.2±7.1%, P<0.001) and infarct growth (60±44.4 mm<sup>3</sup> vs. 130±55.2 mm<sup>3</sup>, P=0.009). K<sub>trans</sub> was significantly lower in the agmatine-treated group compared to the control group (0.05±0.02 min<sup>-1</sup> vs. 0.08±0.03 min<sup>-1</sup>, P=0.012) at 4-hour-reperfusion (Fig 1a, 2). Other permeability parameters were not significantly different between the groups (Table 1). The volume with BBB disruption estimated from the permeability map was significantly less in the agmatine-treated group than in the control group (Fig 1b). The number of factor VIII positive cells was less in the agmatine-treated group than in the control group (3-fold vs. 4-fold compared to contralateral hemisphere, P=0.037).

	Control group (n = 15)	Agmatine-treated group (n = 15)	P value
K <sub>trans</sub> (min <sup>-1</sup> )	0.08±0.03	0.05±0.02	0.012
K <sub>ep</sub> (min <sup>-1</sup> )	0.46±0.3	0.44±0.28	0.856
V <sub>e</sub>	0.39±0.7	0.12±0.06	0.19
Volume of BBB disruption (%)	32.5±16.5	10.4±8.7	<0.001



**Figure 1.** Permeability changes at two different time points. (a) K<sub>trans</sub> values. (b) Brain tissue volume with BBB disruption expressed as a percentage to the ipsilateral hemisphere. Color dots are mean values, the horizontal lines above and below the dots represent 95% confidence intervals. (\* P < 0.05; \*\* P < 0.01)



**Figure 2.** Representative images of MR and immunohistochemical stain. Infarcted areas can be seen as hyperintense lesions on T2-weighted images (a, d). The color-coded permeability maps obtained at 4 hours after reperfusion demonstrate increased permeability in the infarcted areas (b, e). The mean K<sub>trans</sub> values were 0.05±0.02 min<sup>-1</sup> and 0.08±0.03 min<sup>-1</sup> in the agmatine-treated and in the control groups, respectively (P=0.002). On immunohistochemical staining (c, f), the number of new blood vessels detected by factor 8 staining (brown) are less in the agmatine-treated group than in the control group (P=0.037), x200.

**Discussion:** In this study, we found that agmatine protects the BBB in ischemic stroke, and BBB stabilization effect of agmatine can be monitored in vivo by quantification of permeability with DCE-MRI (Fig 2). K<sub>trans</sub> and volume with BBB disruption of the agmatine-treated group were significantly less than those of the control group at 4-hour reperfusion. Our results support the previous study that has shown the protective effects of agmatine on BBB using Evans blue.<sup>2</sup> DCE-MRI provides both permeability values and spatial maps of the permeability changes without killing the animals, which enables us to investigate the BBB-blocking properties of pharmaceutical agents as a longitudinal study by acquiring multiple images at different time-points.

**Conclusions:** Agmatine protects the BBB in ischemic stroke, which can be monitored in vivo by quantification of permeability with DCE-MRI. Therefore, DCE-MRI provides imaging biomarkers for assessing the BBB stabilization properties of pharmacological agents to reduce the complications associated with thrombolytic therapy in ischemic stroke.

## References

1. Tissue plasminogen activator for acute ischemic stroke. The National Institute of Neurological Disorders and Stroke rt-PA Stroke Study Group. N Engl J Med 1995;333:1581-7.
2. Kim JH, Lee YW, Park KA, Lee WT, Lee JE. Agmatine attenuates brain edema through reducing the expression of aquaporin-1 after cerebral ischemia. Journal of cerebral blood flow and metabolism 2010;30:943-9.