

Imatinib reduces blood-brain barrier permeability in a transient occlusion-reperfusion rodent model: A DCE-MRI study

Zamir Merali¹, Jackie Leung¹, and Andrea Kassner^{1,2}

¹Physiology and Experimental Medicine, The Hospital for Sick Children, Toronto, Ontario, Canada, ²Medical Imaging, University of Toronto, Toronto, Ontario, Canada

Introduction: Increased risk of hemorrhagic transformation (HT) limits the general use of thrombolytic therapy in acute ischemic stroke (AIS). Early blood-brain-barrier (BBB) breakdown is believed to be a precursor of HT in AIS and can be assessed by using MR permeability (KPS) imaging.¹ Previous work has shown a correlation between KPS and HT in patients with AIS, and a significant increase in KPS was found in patients that received thrombolytic therapy compared to those who did not.² Agents that can stabilize the BBB such as Imatinib, a platelet-derived growth factor inhibitor, could play an important role in reducing the risk of HT in AIS. One study found that stroke mice given Imatinib had lower BBB leakage and were less likely to proceed to HT after thrombolytic therapy.³ However, the measurements were performed *ex vivo* and, more importantly, the study employed a permanent occlusion model, which neglects reperfusion injury as a factor in the development of HT. We therefore selected a transient occlusion model as a more realistic representation of AIS. The purpose of this study was to use *in vivo* structural and permeability MR imaging to quantify the BBB stabilizing effect of Imatinib in a rodent occlusion-reperfusion model. An Evans Blue assay was used in a subset of animals to validate the MR permeability results.

Materials and Methods: Male Sprague-Dawley rats (n=25) weighing 250-300 grams underwent transient occlusion of the middle cerebral artery using a silicone-coated suture as described by Longa et al.⁴ The suture was removed after 60 minutes to restore perfusion. Rats received either Imatinib (100mg/kg) or an equivalent volume of saline by tail vein injection at 1-hour and 20-hours after reperfusion. Permeability imaging using dynamic contrast-enhanced (DCE) MRI was conducted at 5-hours and 24-hours after reperfusion. MRI was performed on a 3T clinical magnet (Philips Acheiva 3.0T TX) using an 8 channel wrist coil. A 60uL bolus of a gadolinium based contrast agent (Gadovist, 2mmol/mL) was injected via tail vein catheter over 12 seconds shortly after the start of the DCE scan (TR/TE = 6.3/2.2 ms, FOV = 100x85 mm², matrix = 168x142, slice = 1 mm, volumes = 36, time = 4:20 min). In addition, structural T1 and T2 weighted images were acquired to identify infarcted areas and quantify lesion volume. Imaging data was co-registered and analyzed using an in-house tool (MR Analyst v2.1; University of Toronto, Canada) written in MATLAB (Mathworks; Natick, USA). Infarct ROIs were manually defined on each slice of the T2 weighted images and lesion volume was calculated as the total number of voxels. From the DCE-MRI data, mean KPS was calculated in each previously defined ROI using a two-compartment pharmacokinetic model as described by Roberts et al.⁵ A Student's t-test was performed between control and treatment groups to detect significant differences (p<0.05) in KPS as well as lesion volume at the two time points. In addition, Evans Blue dye was injected via tail vein in 3 rats from the treatment and control groups, thirty minutes before sacrifice, to quantify BBB permeability in the CNS tissue *ex-vivo* as previously described.⁶

Results: Nine datasets each from the treatment and control group were included in the final analysis. KPS and infarct size quantified from data at the 5-hour time point were not significantly different between groups. At 24-hours after occlusion, the group treated with Imatinib had reduced infarct size (226mm³±38.6 treatment vs. 288mm³±38.6 control, p<0.05) and KPS (0.104±0.034 treatment vs. 0.173±0.063 control, p<0.05) (Figure 1). Our KPS findings were supported by tissue analysis of Evans Blue extravasation (p<0.05).

Conclusions: Permeability measures derived from DCE-MRI can be used to measure the effect of a BBB stabilizing agent such as Imatinib. We observed that infarct volume and BBB permeability were significantly reduced in animals treated with Imatinib after 24 hours compared to the controls. Further studies will investigate if Imatinib can reduce the risk of HT after administration of a thrombolytic agent.

References:

1. Aksoy D, et al. *Stroke* 2013; 2:e000161.
2. Kassner A, et al. *Am J Neuroradiol* 2009; 30:1864-9.
3. Su EJ, et al. *Nat Med* 2008; 14:731-737.
4. Longa E, et al. *Stroke* 1989; 20:84-91.
5. Roberts H, et al. *Am J Neuroradiol* 2000; 21:891-99.
6. Radu, M, et al. *J. Vis. Exp.* (73), doi:10.3791/50062 (2013).

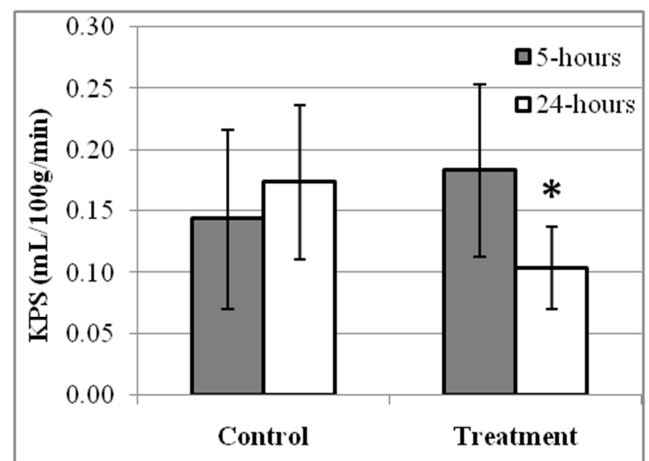


Figure 1 – KPS values at 5 and 24-hours in control and treated rats. (*) marks a significant data point.