

Abnormal grey matter volume correlates with executive dysfunction in attention deficit hyperactivity disorder

Fei Li¹, Ning He², Yuanyuan Li², Xiaoqi Huang¹, Su Lui¹, Lanting Guo², and Qiyong Gong¹

¹Huaxi MR Research Center (HMRR), Department of Radiology, West China Hospital of Sichuan University, Chengdu, Sichuan, China, ²Department of Psychiatry, West China Hospital of Sichuan University, Chengdu, Sichuan, China

Introduction:

Attention deficit hyperactivity disorder (ADHD) is characterized by age-inappropriate degrees of inattention, hyperactivity and impulsivity. Structural neuroimaging studies of ADHD using the magnetic resonance imaging (MRI) suggested that deficit of the specific prefronto-striatal circuit relate to the symptoms of ADHD, and recent morphometric MRI studies reported cerebral structural changes that encompass a number of different large scale brain areas in patients with ADHD [1]. However, the specific neuropsychological dysfunction underlying such atypical brain network profiles remains poorly understood. ADHD patients often exhibit deficiencies in cognitive function, particularly in executive functions such as strategic planning, set switching, cognitive flexibility, and interference inhibition [2], which can be defined by neuropsychological tests such as the Wisconsin Card Sorting Test (WCST) and the Stroop Color-Word Test. A link to executive dysfunction is central to models involving aberrant fronto-subcortical circuits; however, there has been much debate about what core deficit of brain structure might cause the impairments of ADHD. The aims of the present study were to define, in children and adolescents with ADHD, abnormalities of grey matter volume (GMV) using voxel-based morphometry (VBM) analysis based on DARTEL method [3], and to explore the association between these alterations of brain structure and executive dysfunction measured by WCST and the Stroop test, and to investigate the predictive value of GMV in patients with ADHD.

Subjects and Methods:

The study was approved by the local ethical committee and written informed consent was obtained from all subjects. The Structural Clinical Interview for DSM-IV patient edition was used to establish diagnosis for ADHD. A total of 37 drug-naïve, right-handed male children and adolescents with ADHD (mean age 9.9±2.4 years) and 35 right-handed, healthy control males (mean age 10.6±2.3 years) were recruited. The Stroop test and modified Wisconsin Card Sorting Test (WCST) were adopted to assess the executive function for all participants. Differences in executive function tests between ADHD patients and healthy controls were examined by two-sample *t*-test in SPSS 16.0. High resolution T1-weighted images were acquired by a volumetric 3D-SPGR sequence (TR/TE=1900/2.26msec, flip angle=9°, FOV=256x256mm, matrix size=256x256mm, slice thickness=1mm without gap, 176 axial slices) via a Siemens 3T MRI system. VBM with DARTEL was performed using SPM8 included standard five steps [3], and the modulated, normalized and smoothed data were used in two-sample *t*-test statistical analysis between ADHD patients and healthy controls. Significant differences were defined according to a cluster-level threshold of $P<0.05$ using family-wise error (FWE) correction for multiple comparisons. Furthermore, to examine the predictive value of altered GMV discriminating between ADHD and controls, we extracted GMV from the altered peak voxel and performed a series of cross-validation analyses using a predictive linear model in SPSS. In the ADHD group, two-tailed Pearson correlation analyses were performed to assess the relationship between characteristics of executive function tests (WCST and Stroop test) and averaged eigenvalues of altered GMV compared to controls.

Results:

Relative to controls, ADHD patients performed worse on executive function test: in the Stroop test, ADHD patients scored fewer right number, more error numbers and correction numbers, and longer total time ($P<0.001$); in WCST, ADHD patients achieved fewer total correct number ($P=0.002$) and completed categories ($P=0.011$), and made more total errors ($P=0.009$), perseverative errors ($P=0.025$) and non-perseverative errors ($P=0.014$). Compared to healthy controls, ADHD patients had a significant lower GMV in right orbitofrontal cortex (OFC) (BA11) (Talairach: 7,16,-20, 2952 voxels), right precentral gyrus/premotor cortex (BA4/6) (Talairach: 34,-9,57, 1682 voxels), left anterior cingulate cortex (ACC) (BA32) (Talairach: -3,41,1, 2255 voxels) and left posterior cingulate cortex (PCC) (BA31) (Talairach: -7,-7,44, 3947 voxels) ($P<0.05$, FWE corrected) (Figure 1). The left PCC contributed to discrimination between ADHD and controls with an accuracy of 84.9% (sensitivity=88.6%, specificity=81.1%); the right precentral gyrus/premotor cortex contributed to this discrimination with an accuracy of 83.4% (sensitivity=82.9%, specificity=83.8%); the right OFC contributed to this discrimination with an accuracy of 80.9% (sensitivity=91.4%, specificity=70.3%); the left ACC contributed to this discrimination with an accuracy of 80.3% (sensitivity=71.4%, specificity=89.2%), highly significant at $P<0.001$ for the four analyses (Figure 2). In ADHD patients group, the GMV in right precentral gyrus/premotor cortex and left PCC are negatively correlated to total time in Stroop test, and GMV in left posterior cingulate cortex was negatively correlated to completed categories in WCST (Figure 3).

Conclusion:

The present study characterized lower GMV in prefrontal and cingulate cortex in children and adolescents with ADHD compared with healthy controls, and suggested the deficit motor and attention related area having an important role in pathogenesis in ADHD at the early course of illness, which yielded high classification accuracy discriminating between ADHD and controls. Furthermore the lower GMV related to motor and attention function in ADHD correlated with the executive dysfunction, such as the defects in inhibitory control reflected by Stroop test and the impact cognitive flexibility reflected by WCST, pointing to a GMV-based pathophysiological process in ADHD and relevant to understanding relationships between neural substrate and executive function in ADHD.

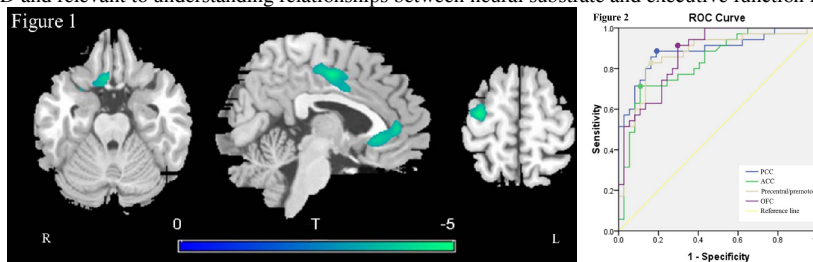


Figure 1. Brain regions with lower GMV in ADHD patients compared with the controls including right precentral gyrus/premotor cortex and OFC, left ACC and PCC.

Figure 2. Receiver Operating Characteristic curve for the discrimination between ADHD patients and controls using the values of four regions with altered GMV.

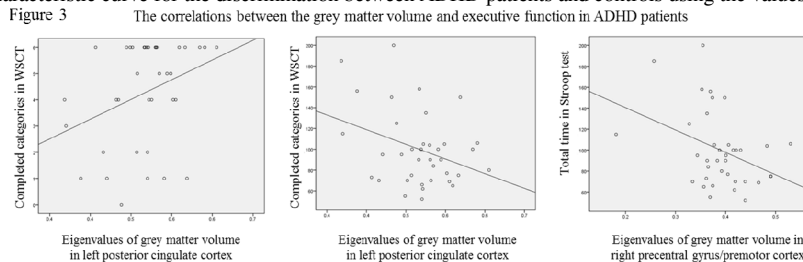


Figure 3. The associations between the GMV of left PCC and right precentral gyrus/premotor cortex and executive function measured by Stroop test and WCST.

Reference:

1. Castellanos, F.X. and E. Proal, Large-scale brain systems in ADHD: beyond the prefrontal-striatal model. *Trends Cogn Sci*, 2012. 16(1): p. 17-26.
2. Kipp, K., A developmental perspective on the measurement of cognitive deficits in attention-deficit/hyperactivity disorder. *Biol Psychiatr*, 2005. 57(11): p. 1256-60.
3. Ashburner, J., A fast diffeomorphic image registration algorithm. *Neuroimage*, 2007. 38(1): p. 95-113.