

The effect of weight loss on brain microstructure in obese middle-aged women

Clifford Chan¹, Heather Collins¹, Patrick M O'Neil², Joshua Brown², Joseph A Helpert¹, and Andreana Benitez¹

¹Department of Radiology and Radiological Sciences, Medical University of South Carolina, Charleston, South Carolina, United States, ²Weight Management Center, Department of Psychiatry and Behavioral Sciences, Medical University of South Carolina, Charleston, South Carolina, United States

INTRODUCTION: Almost 40% of middle-aged adults in the US are obese¹ and are at 74% greater risk for developing dementia compared to normal weight peers². A higher body mass index (BMI) has been associated with atrophy of both gray and white matter (WM), in regions that preferentially degenerate with age and demonstrate early pathological signs of dementing diseases³. Although these observations suggest that weight loss could be an effective strategy for dementia prevention, no human studies have directly tested whether weight loss is associated with favorable brain changes measured through diffusion MRI. **Purpose:** This preliminary study reports changes in Diffusional Kurtosis Imaging (DKI) metrics before and after weight loss in obese middle-aged women. **Target Audience:** Clinical researchers interested in neuroimaging biomarkers of aging and obesity.

METHODS: This IRB-approved study recruited 7 obese middle-aged women from the MUSC Weight Management Center Focus Program, a ~15-week diet- and exercise-mediated weight loss program (mean age=58.8±4.9, range=52-64; baseline BMI=34.9±5.0). These patients lost an average of 11% of their baseline body weight at 16.8±1.8 weeks follow-up. Six women comprise the passive control group (mean age=66.7±4.8, range=62-73) who completed follow-up scans after 12.5±0.7 weeks. Both groups completed baseline (i.e. pre-Focus program for the patients) and follow-up MRI on a 3T Trio MR system (Siemens). DKI acquisition was performed with 3 b-values (0, 1000, 2000 s/mm²) along 64 diffusion encoding directions using single-shot twice-refocused-EPI. Other DKI parameters were: TR=8300ms, TE=103ms, averages=1, FOV=220×220mm², slice thickness=2.5mm³. Post-processing using Diffusional Kurtosis Estimator (<http://nitrc.org/projects/dke>) provided parametric maps of the diffusion metrics. All parametric maps were normalized to the 1×1×1mm³ MNI152 standard space. Two types of analyses were conducted: 1) WM regions of interest (ROI) analyses were identified using the JHU atlas. ROI analyses were conducted per DKI metric. As an exploratory approach, the metric differences between baseline and follow-up in these regions were computed and compared between groups using independent samples t-tests. Repeated measures analyses of covariance (ANCOVAs; covariate=age) were conducted on the regional metrics that demonstrated t-test differences. 2) Voxelwise analyses were performed with TBSS running in FSL with analyses performed only in WM skeleton voxels. Permutation-based statistics were computed using FSL Randomise (2,000 permutations). Analyses of covariance were conducted to test the differences between baseline and follow-up DKI maps between patients and controls, covarying for age.

RESULTS: 1) Repeated measures ANCOVAs of the ROIs identified increased mean kurtosis (MK) and radial kurtosis (RK) in both the cingulum and the superior fronto-occipital fasciculus in the right hemisphere for only the patient group at follow-up (all $p < 0.05$), controlling for age, with very large effect sizes ($\eta^2 = 0.33-0.46$; Figure 1). 2) TBSS analysis results corroborate the right hemisphere focus of these changes in MK, although threshold-free cluster enhancement correcting for familywise error from multiple comparisons was $p = 0.20$ (Figure 2). TBSS analysis results for RK was at a corrected $p = 0.39$.

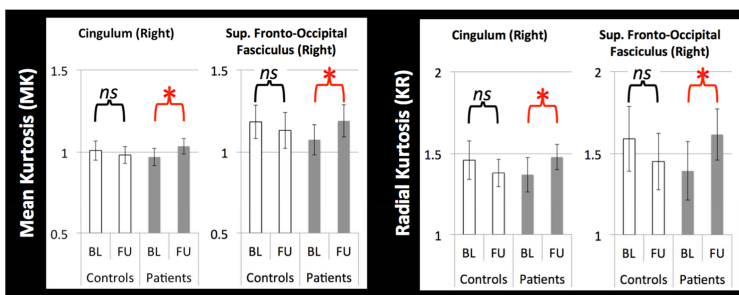


Figure 1. MK and RK of the cingulum and superior fronto-occipital fasciculus in the right hemisphere at baseline (BL) and follow-up (FU) for the controls and patients.

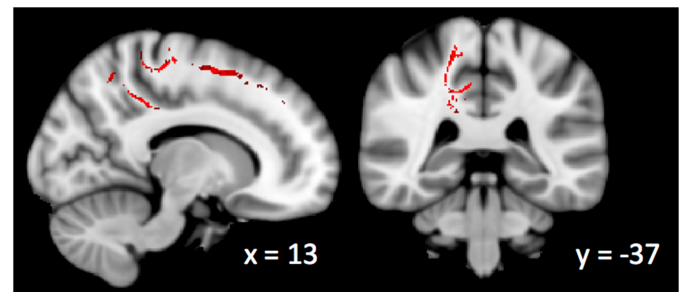


Figure 2. TBSS results (red) showing increased MK in the right hemisphere at follow-up for the patients (images in radiologic convention, R=L).

DISCUSSION: Increased MK and RK may suggest enhanced myelin integrity in right hemisphere limbic and association WM tracts due to weight loss, but verification of these findings in a larger sample and with an age- and BMI-matched control group is warranted.

Conclusion: This preliminary study shows that DKI metrics can reflect improvements in brain microstructure associated with weight loss, providing an in vivo method with which to further investigate the potential neural mechanisms underlying these changes.

REFERENCES: ¹Cynthia et al. Prevalence of obesity among adults; US 2011-2012. *NCHS Data Brief*. 2013;131. ²Whitmer et al. Obesity in middle age and future risk of dementia. *BMJ*. 2005;330:1360-0. ³Raji et al. Brain structure and obesity. *Hum Brain Mapp*. 2010;31:353-364.