

Resting State Network Development in Very Preterm Infants

Lili He¹ and Nehal A. Parikh^{1,2}

¹Center for Perinatal Research, The Research Institute at Nationwide Children's Hospital, Columbus, Ohio, United States, ²Department of Pediatrics, The Ohio State University College of Medicine, Columbus, Ohio, United States

INTRODUCTION: Very preterm infants experience significantly increased risk of motor, cognitive and behavioral impairments. However, conventional diagnosis of these impairments cannot be made until early childhood. Novel and reproducible techniques, available soon after birth, are needed to fill this gap. Resting-state functional connectivity magnetic resonance imaging (rs-fcMRI) is a task-free tool that can be safely performed in infants soon after birth to gain insights into functional brain networks associated with motor, cognitive, and behavioral development. In our present longitudinal study, we followed a cohort of very preterm infants to validate resting state networks (RSNs) that were observed in the pioneering work by [1-3] during the early preterm period (32 weeks postmenstrual age [PMA]) and at term-equivalent age (40 weeks PMA). As some networks were not fully developed to adult-like patterns or not examined, we extended our analysis to include rs-fcMRI studies to 52 weeks PMA. Our aim was to identify the perinatal developmental windows for major RSNs and explore RSN maturation three months after term-equivalent age. Such information gained may be applied towards the development of prognostic neural biomarkers soon after birth for motor, cognitive and/or behavioral deficits to facilitate preventive early interventions for high-risk very preterm infants.

METHODS: Our study was approved by the Institutional Review Board of Nationwide Children's Hospital. Thirty-five very preterm infants were imaged sequentially at 32, 39 and 52 weeks PMA. All subjects were scanned during natural sleep. A total of 65 high-quality datasets were available for analysis, including 19, 21, & 25 datasets at 32, 38, & 52 weeks PMA, respectively. Infants were scanned on a 3T GE HDX scanner. Functional images were collected utilizing a single shot echo planar imaging sequence sensitized to T2*-weighted BOLD signal changes (repetition time/echo time = 3000/35 ms, voxel size 3 mm³, flip angle 90°, field of view 180mm, matrix size 64 x 64, slice thickness 3.0mm). Prior to data processing, we excluded the first 10 time points from rs-fcMRI data to allow magnetic equilibration. For the data preprocessing, we used FSL routines in FMRIB Software Library (FMRIB, Oxford, UK) [4]. Next, we stripped nonbrain tissues and corrected slice dependent time shifts and head movements. We spatially normalized the realigned rs-fcMRI data and T2-weighted images to the Imperial College London neonate brain template space [5]. To remove both low frequency scanner drift artefacts and the noise associated with cardiac and respiratory oscillations, we applied a temporal band-pass filter for frequencies between 0.01 and 0.08 Hz. We also applied a spatial Gaussian isotropic filter with full width at half maximum of 5 mm (to improve signal to noise ratio) and global intensity normalization (to keep overall signal mean constant across subjects and sessions). We identified spontaneous brain activities at rest using the temporal concatenation version of probabilistic independent components analysis (ICA) implemented in MELODIC (multivariate exploratory linear decomposition into independent components) in FSL. In the Imperial College London neonate brain template space, for each subject, we extracted time series from individually identified RSN in each brain hemisphere, for which the mean time series were calculated. Functional connectivity was estimated using a partial correction approach; correlation coefficients were then converted to a normal distribution using Fisher's z transformation. Finally, we performed the test of connectivity differences among different gestational age groups by employing multiple comparisons at $P=0.05$ significance level.

RESULTS: We selected the components/RSNs of interest (Fig. 1) based on both temporal characteristics and anatomical localization (visually compared with previously published and publically available RSNs template) [6]. The interhemispheric connectivity significantly increased with increasing PMA for the auditory, somatosensory and subcortical gray matter networks (Fig. 2). More specifically, for auditory network, interhemispheric connectivity increased from 39 to 52 weeks PMA ($P=0.04$); somatosensory network showed significant increase from 32 to 52 weeks PMA ($P=0.04$); subcortical gray matter network showed significantly stronger interhemispheric connectivity at 52 than at both 39 and 32 weeks PMA ($P=0.001$ and $P=0.01$, respectively). For the complex networks (except for DMN [includes medial prefrontal, posterior cingulate and lateral parietal cortex]), connectivity also significantly increased with PMA. Specifically, visual network (includes medial visual, occipital visual and lateral visual cortex) connectivity increased from 32 to 52 weeks PMA ($P=0.01$); executive network (includes anterior cingulate cortex, medial prefrontal cortex and superior/middle frontal gyrus) connectivity at 52 weeks PMA was significantly stronger than at 39 and at 32 weeks PMA ($P=0.02$ and $P=0.003$, respectively); and frontoparietal network (includes frontal gyrus and inferior parietal cortex) connectivity at 32 weeks PMA was significantly weaker than at 39 and 52 weeks PMA ($P<0.001$ and $P<0.001$, respectively). Connectivity remained stable without change at 32, 39, and 52 weeks PMA for the motor, cerebellar, brainstem, and default mode networks.

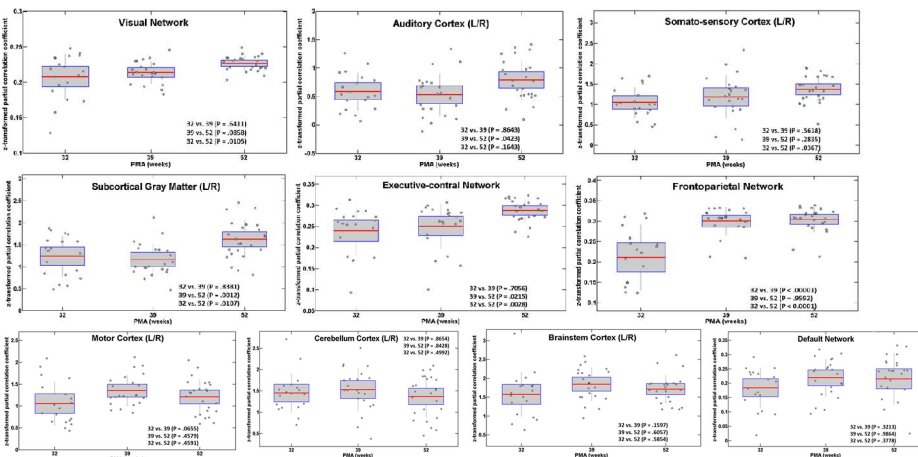


Fig. 2. Functional connectivity development at 32, 39, and 52 weeks PMA for 10 RSNs in very preterm infants.

For visual, executive-control and frontoparietal networks, the connectivity was calculated as the mean of the correlation coefficients between the different pair of nodes within each network.

CONCLUSIONS: We observed the presence of several important RSNs, that resembled patterns observed in adults, as early as 32 weeks postmenstrual age in a cohort of very preterm infants. Additionally, most of the networks demonstrated a gradual increase in connection strength with increasing postnatal maturation within the first 6-7 months after preterm birth. This study supports and expands the findings of a handful of prior investigations. Very preterm infants are at high risk for long-term abnormal motor, cognitive and behavioral development. Emerging evidence demonstrates that RSNs are relevant and may reflect neuronal and anatomical network connectivity. Investigating the earliest manifestations of brain functional networks may facilitate early prognostic and intervention in very preterm infants at highest risk for long-term impairments.

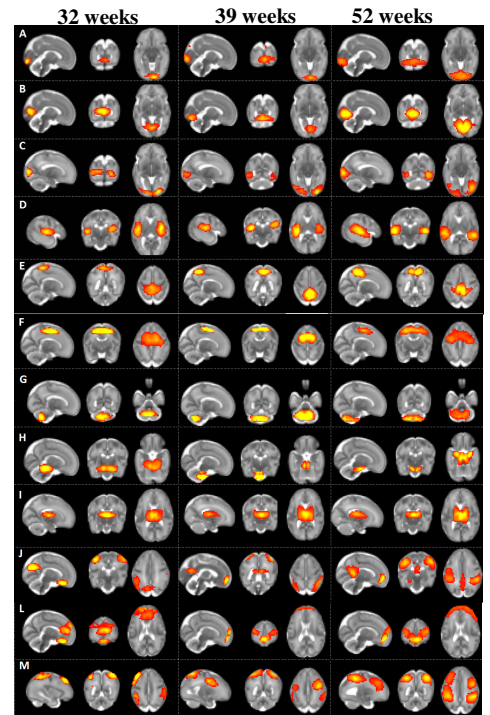


Fig. 1. Resting-state networks identified using probabilistic ICA. (A) occipital visual; (B) medial visual; (C) lateral visual; (D) auditory; (E) motor; (F) somatosensory; (G) cerebellum; (H) brainstem; (I) subcortical gray matter; (J) default mode; (K) executive control; and (M) frontoparietal.

REFERENCES

- Fransson et al., Proc Natl Acad Sci 2007; 104:15531-36.
- Doria et al., Proc Natl Acad Sci USA 2010; 107: 20015-20.
- Smyser et al., Cereb Cortex 2010; 20: 2852-62.
- Jenkinson et al., Neuroimage 2012; 62:782-790.
- Kuklisova-Murgasova et al., Neuroimage 2011; 54: 2750-63.
- Smith et al., Proc Natl Acad Sci USA 2009; 106: 13040-45.