

# Quantitative analysis of global pattern of early cortical folding in polymicrogyria fetal brains

Kiho Im<sup>1</sup>, Alexandre Guimaraes<sup>1</sup>, Borjan Gagoski<sup>1</sup>, Caitlin Rollins<sup>1</sup>, Edward Yang<sup>1</sup>, and P. Ellen Grant<sup>1</sup>  
<sup>1</sup>Boston Children's Hospital, Harvard Medical School, Boston, MA, United States

## TARGET AUDIENCE

Researchers in the field of fetal MRI analysis, Pediatric Neurologists/Neuroradiologists as well as Neuroscientists interested in normal and abnormal brain development.

## PURPOSE

In human fetal brain development, spatio-temporal patterns of early cortical folding are hypothesized to show little variability between subjects due to tight genetic control. Defects in neurodevelopmental process in many genetic brain malformations and psychiatric/neurological disorders result in disrupted global pattern of cortical folding, which may appear in early fetal stage. Unlike prior studies that simply used gyrification index, cortical curvature, or depth<sup>1,2</sup>, this study aims to investigate global patterns of early cortical folding and anatomically label primary sulci in individual human fetal brains. We analyzed typically developing (TD) and polymicrogyria (PMG) fetal brains by comparing with normal fetal brain templates, and hypothesized that our quantitative sulcal pattern analysis would detect abnormal cortical growth in the PMG fetuses compared to the typical controls in the third trimester of fetal life.

## METHODS

Eight TD and 5 PMG fetuses were included in the present study (age range, TD: 22 – 27 weeks gestational age [GA], PMG: 22 – 29 weeks GA), and 3T single shot T2 weighted (HASTE) images for their brains were acquired multiple times in different orientations. PMG was finally confirmed with postnatal imaging. Fetal head motion was corrected and isotropic high-resolution volume ( $0.75 \times 0.75 \times 0.75$  [mm]) was reconstructed using these multiple images<sup>3</sup>. The volume images of each subject were manually aligned along the anterior and posterior commissure points. Cortical plate area was semi-automatically segmented on the images using the FreeView software (surfer.nmr.mgh.harvard.edu) and 3D inner cortical plate surface was reconstructed using the isosurface function from the Matlab software. We used 9 fetal brain templates from 23 to 31 weeks GA as a reference in sulcal pattern analysis, which were previously published and freely accessible (biomedic.doc.ic.ac.uk/brain-development)<sup>4</sup>. The cortical plate surfaces of the fetal templates were also reconstructed using the same process. Mean curvature and sulcal depth on a surface model were measured using the FreeSurfer software (surfer.nmr.mgh.harvard.edu) and sulcal catchment basins were automatically defined using a watershed algorithm<sup>5</sup>. For the templates, we manually assigned 19 anatomical labels of primary sulci to these sulcal basins (insula [Sylvian fissure], central, superior frontal, middle frontal, inferior frontal, precentral, postcentral, intraparietal, superior temporal, inferior temporal, occipito-temporal, collateral, orbital, olfactory, cingulate, subparietal, lateral occipital, calcarine, and parieto-occipital sulci). Relative 3D position ( $x$ : right – left [0 – 1],  $y$ : anterior – posterior [0 – 1],  $z$ : inferior – superior [0 – 1]), normalized surface area ( $a$  = area/whole cortical surface area), and mean sulcal depth ( $d$ ) were computed for each sulcal basins, which were irrelevant to brain size. Global sulcal pattern was represented with a feature set of sulcal basins including not only the local sulcal features (feature vector  $F(i) = (x_i, y_i, z_i, a_i, d_i)$ , sulcal basin  $i$ ) but also inter-sulcal relationships,  $F(i) - F(j) = (x_i - x_j, y_i - y_j, z_i - z_j, a_i - a_j, d_i - d_j)$ , in the left and right whole hemispheres<sup>5</sup>. In order to measure normality/abnormality of sulcal pattern for each TD and PMG fetus, individual sulcal feature sets were compared to the set of all 9 fetal brain templates using a spectral-based sulcal pattern matching and comparison technique<sup>5,6</sup>. We determined the optimal match having the minimum difference of the sulcal features between the individual fetus and fetal templates, and then computed the value of sulcal pattern similarity, which ranged from 0 to 1 (Fig. 1). Since the primary sulci were anatomically pre-labeled in the fetal templates, the sulcal folds of individual fetus were automatically labeled. Our method allowed variable weighting of the features, to assess their relative importance on sulcal pattern similarity. Accordingly, we evaluated the impact of each individual feature on similarity measures by setting all weights of the other features to 0. The sulcal pattern similarities to the normal templates were statistically compared between TD and PMG fetuses using the Mann-Whitney  $U$  test.

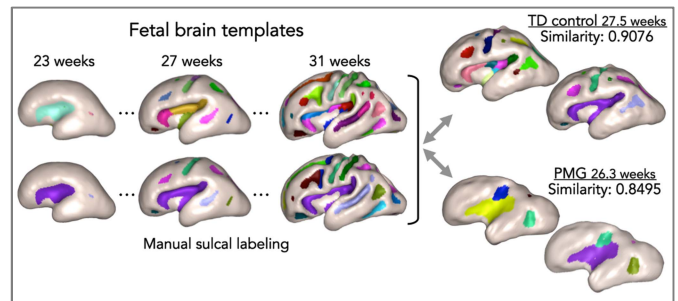


Fig. 1. Sulcal pattern matching and similarity measure with normal fetal templates and automatic sulcal labeling for individual fetal brains

## RESULTS

The PMG fetuses showed significantly lower similarity to the normal templates in the left and right hemispheric sulcal patterns measured with the whole set of features (left:  $p = 0.010$ , right:  $p = 0.029$ ) (Fig. 2). Additional statistical tests were performed for each individual feature separately for each hemisphere. In the left hemisphere, significantly lower sulcal pattern similarities to the templates were observed in the PMG group for relative 3D position ( $p = 0.029$ ) and sulcal depth ( $p = 0.019$ ), but not for normalized sulcal basin area ( $p = 0.524$ ). In the right hemisphere, there were no significant group differences in individual feature-based sulcal pattern similarity (position:  $p = 0.354$ , area:  $p = 0.093$ , depth:  $p = 0.284$ ).

## DISCUSSION

Primary sulcal folding pattern may be related to the early patterning of cortical functional areas and their anatomical neuronal connections. Cortical areas do not develop independently but rather in relation to other functional areas, and accordingly give rise to specific patterns of sulcal folds. Here the sulcal pattern comparison method characterized interrelated sulcal arrangement and patterning in the global cortical area, and effectively detected abnormal global patterns of early primary sulci in PMG in both hemispheres. We suggest that our quantitative method can help to identify and quantify abnormal early cortical organization even in the third trimester of fetal life before cortical folding pattern is fully determined.

## CONCLUSION

Our sulcal pattern analysis shows potential for providing a quantitative and reliable means for identifying abnormal brain development in fetal stage. This method might be helpful in catching early signs of abnormal cortical growth that may be visually missed, and may provide quantitative data to explore correlations with genotype and outcome.

## REFERENCES

1. Wright, R., et al. *NeuroImage* **91**, 21-32 (2014).
2. Clouchoux, C., et al. *Cerebral cortex* **23**, 2932-2943 (2013).
3. Kuklisova-Murgasova, M et al. *Medical image analysis* **16**, 1550-1564 (2012).
4. Serag, A., et al. *NeuroImage* **59**, 2255-2265 (2012).
5. Im, K., et al. *NeuroImage* **57**, 1077-1086 (2011).
6. Im, K., et al. *Cerebral cortex* **23**, 3007-3015 (2013).

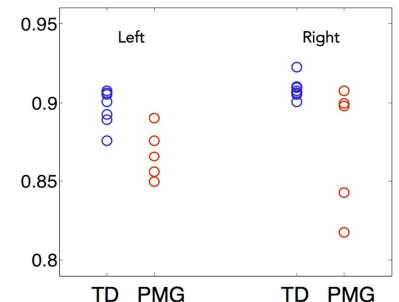


Fig. 2. Scatter plot of similarity values to the normal fetal templates